

**STATE BOARD OF OPTOMETRY**

2450 DEL PASO ROAD, SUITE 105, SACRAMENTO, CA 95834
P (916) 575-7170 F (916) 575-7292 www.optometry .ca.gov



Continuing Education Course Approval Checklist

Title:

Provider Name:

☒ Completed Application

Open to all Optometrists? ☒ Yes ☐ No

Maintain Record Agreement? ☒ Yes ☐ No

☒ Correct Application Fee

☒ Detailed Course Summary

☒ Detailed Course Outline

☒ PowerPoint and/or other Presentation Materials

☐ Advertising (optional)

☒ CV for EACH Course Instructor

☒ License Verification for Each Course Instructor

Disciplinary History? ☒ Yes ☐ No



STATE BOARD OF OPTOMETRY
2450 DEL PASO ROAD, SUITE 105, SACRAMENTO, CA 95834
P (916) 575-7170 F (916) 575-7292 www.optometry.ca.gov



CONTINUING EDUCATION COURSE APPROVAL APPLICATION

\$50 Mandatory Fee

Pursuant to California Code of Regulations (CCR) § 1536, the Board will approve continuing education (CE) courses after receiving the applicable fee, the requested information below and it has been determined that the course meets criteria specified in CCR § 1536(g).

In addition to the information requested below, please attach a copy of the course schedule, a detailed course outline and presentation materials (e.g., PowerPoint presentation). Applications must be submitted 45 days prior to the course presentation date.

Please type or print clearly.

Course Title (3) TOPIC LECTURES OCULAR SURFACE DISEASE	Course Presentation Date 11/01/2016
---	--

Course Provider Contact Information

Provider Name WENDY (First)	MCEL RATH (Last)	LEE (Middle)
Provider Mailing Address 1515 RIVER PARK DRIVE Street SUITE 100 City SACRAMENTO State CA Zip 95815		
Provider Email Address wendym@saceye.com		
Will the proposed course be open to all California licensed optometrists?		<input checked="" type="checkbox"/> YES <input type="checkbox"/> NO
Do you agree to maintain and furnish to the Board and/or attending licensee such records of course content and attendance as the Board requires, for a period of at least three years from the date of course presentation?		<input checked="" type="checkbox"/> YES <input type="checkbox"/> NO

Course Instructor Information

Please provide the information below and attach the curriculum vitae for each instructor or lecturer involved in the course. If there are more instructors in the course, please provide the requested information on a separate sheet of paper.

Instructor Name PATRICIA SAMUEL JACOB (First)	SIERRA, MD LEE, MD BRUBAKER, MD (Last)	BENRIZ HYUNG WELLINGTON (Middle)
PATRICIA SIERRA, MD - A82588 License Number SAMUEL LEE, MD - A110394 JACOB BRUBAKER, MD - A124655		License Type MEDICAL BOARD OF CALIFORNIA
Phone Number (916) 649-1515		Email Address PSIERRA@SACEYE.COM SLEE@SACEYE.COM JBRUBAKER@SACEYE.COM




I declare under penalty of perjury under the laws of the State of California that all the information submitted on this form and on any accompanying attachments submitted is true and correct.

SIGNATURES ATTACHED

Signature of Course Provider

30 AUGUST 2016

Date

Course Title	Date(s) of Course	Instructor(s)/Lecturer(s)	CE Hours Requested	FOR BOARD USE <u>ONLY</u>		
				Approved	Disapproved	ID #
OCULAR SURFACE DISEASE IN CATARACT AND REFRACTIVE SURGERY	11-1-16	PATRICIA B. SIERRA, MD	1.0			
		 8-30-16				
DRY EYES: AN IMMUNE-MEDIATED OCULAR SURFACE DISEASE	11-1-16	SAMUEL H. LEE, MD	1.0			
		 8/30/16				
OCULAR SURFACE DISEASE DUE TO GLAUCOMA MEDICATIONS	11-1-16	JACOB W. BRUBAKER, MD	1.0			
		 8/30/16				
COMMITTEE COMMENTS:						



SACRAMENTO EYE CONSULTANTS

August 30, 2016

State Board of Optometry
2450 Del Paso Road, Suite 105
Sacramento, CA 95834

RE: Related Topics

To whom it may concern:

The main topic of our meeting will be "Ocular Surface Disease" and this topic will be split among three of the lecturers: Dry Eyes as an Inflammatory Disease; Glaucoma medications and Dry Eyes, and Eye Surgery and Dry Eyes.

These topics are all related to dry eyes, looking at it from three different aspects.

Please contact me if you have any questions.

Thank you.

Wendy McElrath COA

Wendy McElrath, COA
Sacramento Eye Consultants
E-mail: wendym@saceye.com

Ocular Surface Disease in Refractive and Cataract Surgery

Patricia B. Sierra, MD

Summary:

Dry eye is a pervasive disease among our patients; many go undiagnosed or incompletely treated. In preparation for cataract and refractive surgery, the diagnosis and treatment of dry eye is of outmost importance to successful postoperative results.

Our patient's expectations following cataract and refractive surgery continue to increase. The examination of the ocular surface during the preoperative evaluation is critical. It gives us the opportunity to educate the patient on the existence of the condition and initiate treatment in order to prepare the ocular surface for an accurate refraction prior to LASIK and for corneal measurements necessary for intraocular lens calculations.

The recommended treatment will depend on the type of ocular surface condition in a particular patient. Most patients will fall in one of two categories: aqueous deficient or evaporative dry eye. Some patients will have both components and should be treated with a combination of therapies as well as behavior modification.

Evaluation of the ocular surface is also important following the surgical procedure as there a risk of some degree of worsening of the dry eye related to the trauma of surgery, corneal incisions and toxicity of medications.

In summary, the evaluation and treatment of dry eyes before and after cataract and refractive surgery is critical for outstanding postoperative results and happy patients.

Ocular Surface Disease in Cataract and Refractive Surgery
Current Treatment Recommendations – Patricia Sierra, MD

Objectives

At the conclusion of this presentation, participants should be able to:

- Recognize various signs of conjunctival and corneal inflammation related to ocular surface disease.
- Perform appropriate clinical tests to assess tear quality and quantity.
- Determine the difference between aqueous deficient and evaporative dry eye
- Compare clinical finding of various corneal and conjunctival conditions that can be related or mimic dry eye syndrome.
- Apply current recommendations for the treatment dry eyes
- Understand the importance of treating ocular surface diseases in preparation for cataract and refractive surgery.

I. Introduction

Impact of ocular surface disease on cataract and refractive surgery

II. Understanding etiology of dry eyes.

Brief description of aqueous deficient and evaporative dry eye and

The inflammatory mechanism involved in dry eye syndrome

IV. Clinical examination

Assessing tear quality, quantity and severity of the disease

Evaluating associated eyelid, conjunctival and orbital abnormalities

V. Treatment

Dry eye treatment options in 2016

DEWS (International Dry Eye Workshop) recommendations for treatment

Surgical options to reduce dry eyes

Ocular Surface Disease in Cataract and Refractive Surgery

Patricia B. Sierra, MD

Cataract Surgery

- Cataract is one the most commonly performed surgical procedures in the US
 - Increasing rates of cataract surgery
 - Increasingly safe and effective
 - Higher patient expectations
 - Improved technology offers opportunity to decrease spectacle dependence and uncorrected visual acuity following surgery.

Impact of Ocular Surface

- Much more common than previously thought
- 60% of cataract patients (aged 70 years on average) show signs of dry eyes in the absence of symptoms.
- 59% of patients scheduled for cataract surgery were found to have blepharitis.

Dry Eye and Refractive Surgery

- Many patients who seek LASIK already have dry eyes.
- CL intolerance is usually an indication of dry eyes and a common reason for LASIK consultation
- Dry eye is common after LASIK and symptoms can persist for months following procedure.

Risk Factors

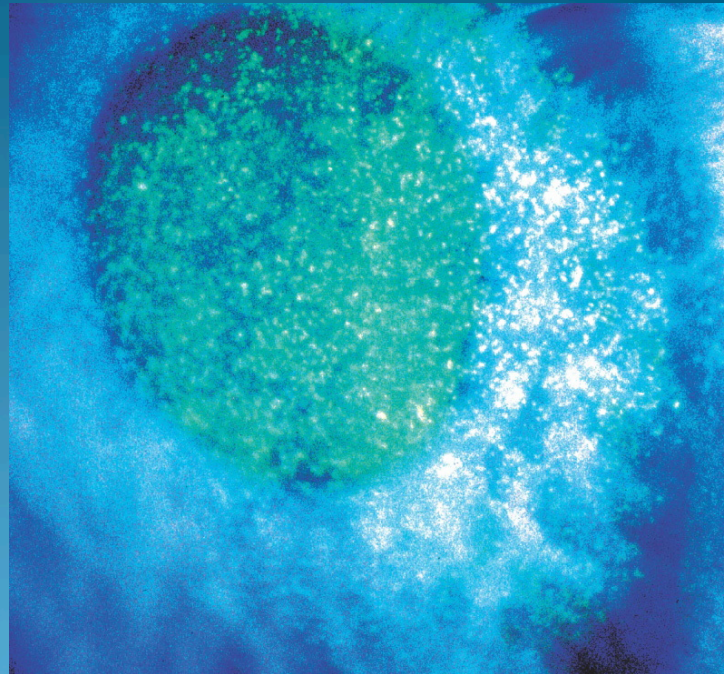
- Females >40 years-old
- Antihistamines
- Antidepressants
- Contraceptives
- Acne medication (Acutane)
- Autoimmune conditions
- Dry environment

Inflammation and Ocular Surface

- Dry eye and blepharitis compromise the integrity and normal function of the tear film and can impact visual and surgical outcomes.
- The pre-corneal tear film is the most anterior refractive interface of the eye and, with the cornea, accounts for $2/3$ of the eye's total optical power.
- Tear film break-up can create optical aberrations and reduce image quality.

Preexisting Dry eye

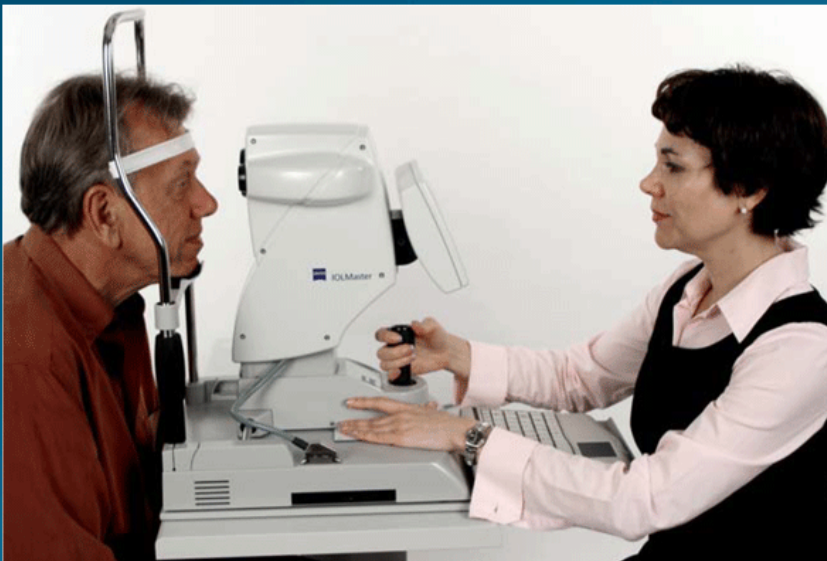- Can lead to inaccurate manifest refraction, keratometry and IOL power calculations in surgical planning.



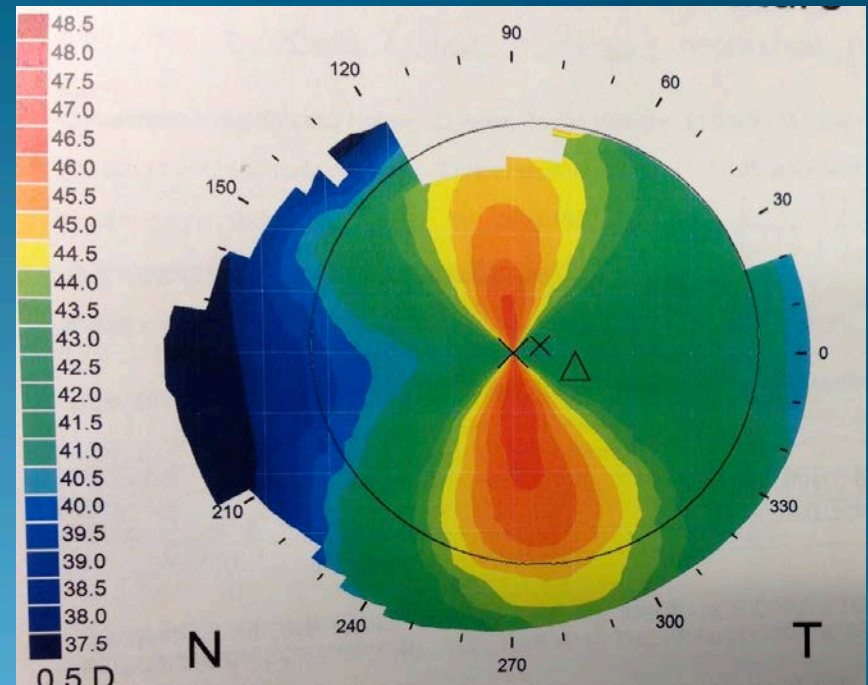
Inacurate Calculations

AL measurement
Optical Biometry

Keratometry and
topography



After incorporating digital signal processing and other software improvements, the IOLMaster is faster, provides more user feedback regarding quality of current data acquisition conditions, and can accurately measure a much greater percentage of eyes.



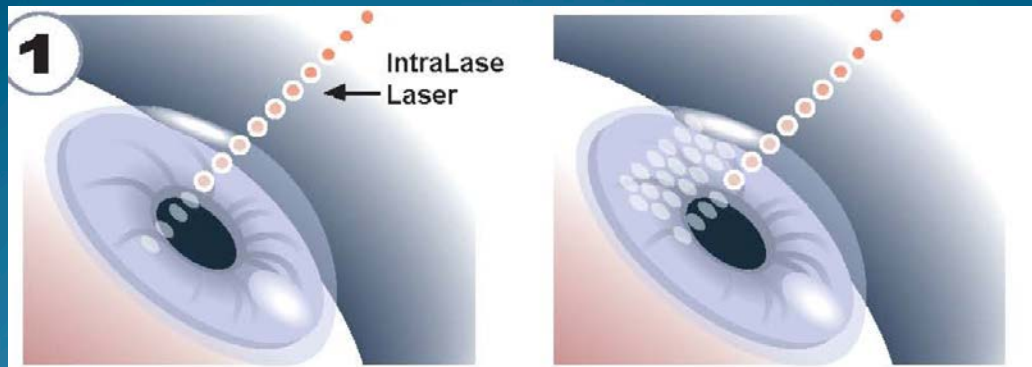
Dry Eyes

- Is specially problematic when determining refraction and calculating for toric and multifocal IOLs
- Needs to be controlled prior to surgery to improve visual results and surgical outcomes.

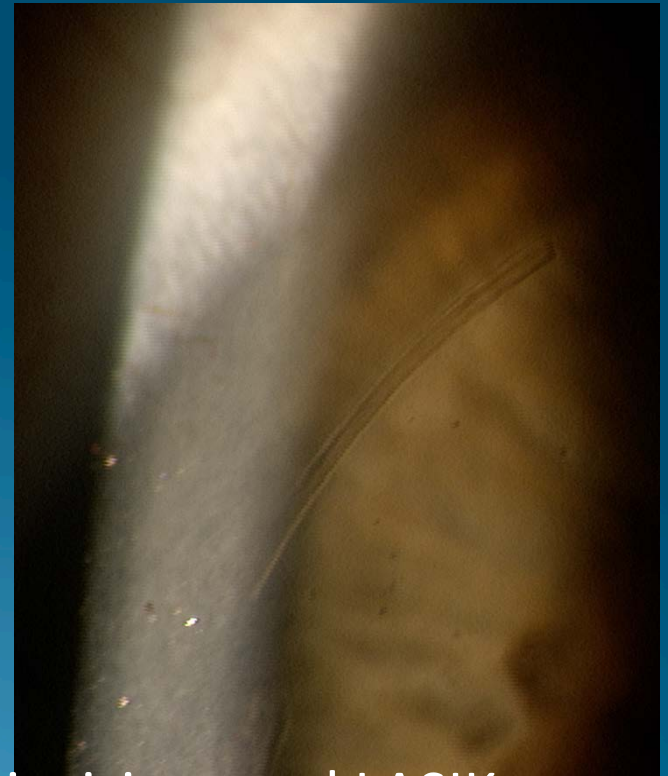
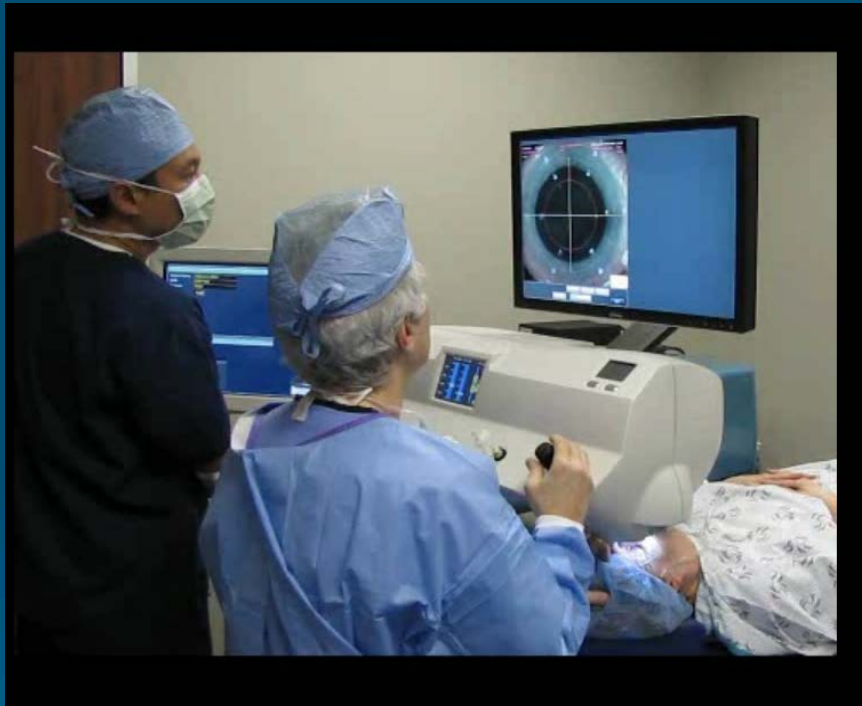
Dry Eye after surgery

- Can worsen after cataract and refractive surgery
- Can increase the risk of secondary infection after surgery
- Can slow wound healing and visual recovery

LASIK Induced Dry Eye

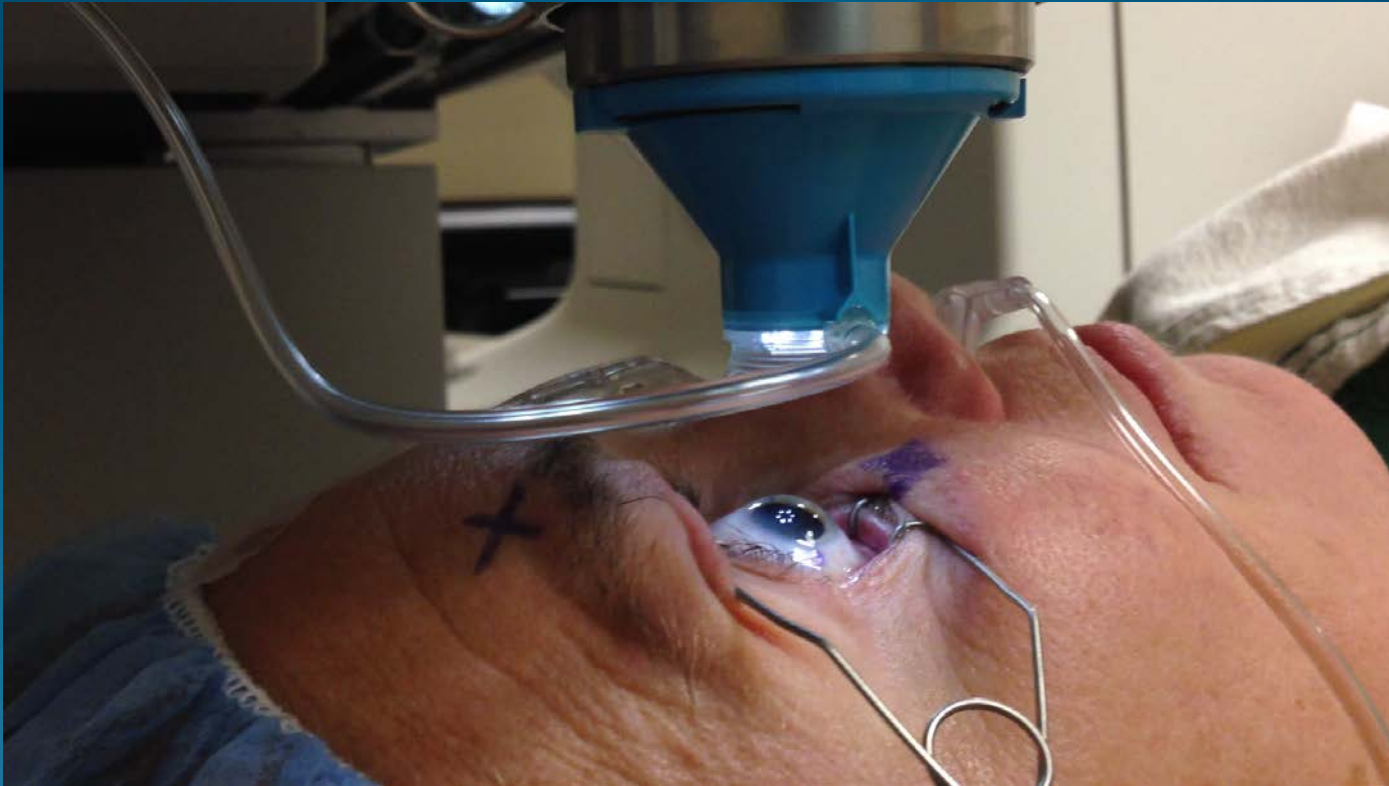


Corneal incisions



Corneal incisions (limbal relaxing incisions and LASIK flaps) and cause decreased corneal sensation and worsen preexisting dry eye.

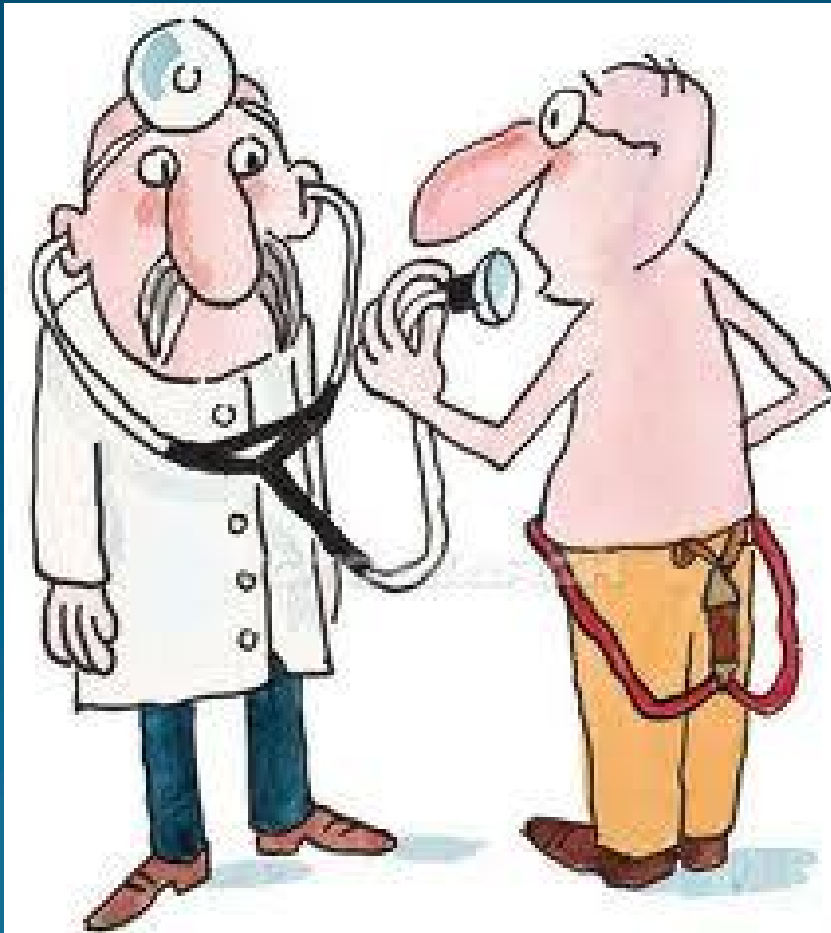Ocular Surface Trauma



Preoperative Screening

- Questionnaires- help identify potential dry eye patients
- Objective tests:
 - Tear Osmolarity
 - MMP
 - Tear film studies
 - Schirmer's

Listen to Patient Complaints



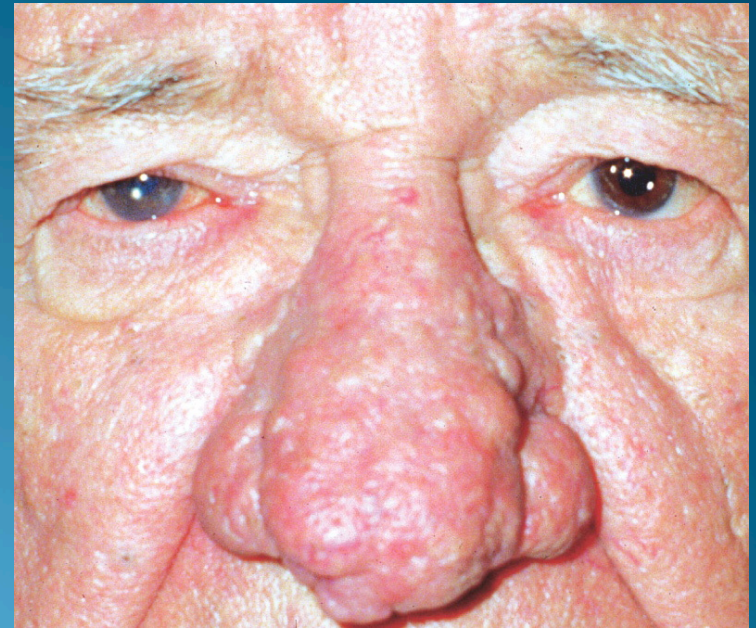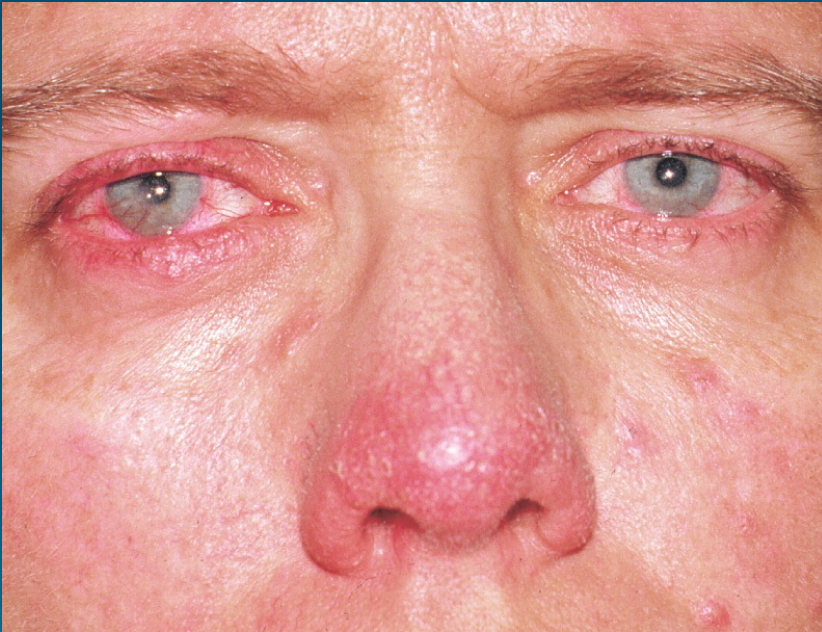- Fluctuating vision
- Ocular discomfort
- Photophobia

Clinical Examination

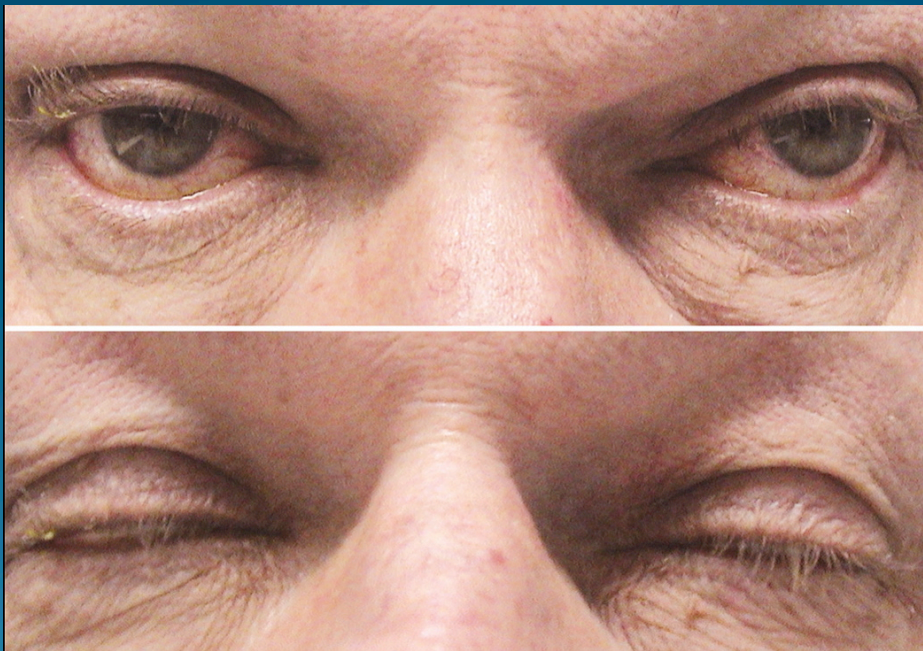Stepwise approach to exam:

1. The eyelids and lashes
2. The tear meniscus
3. Tarsal and bulbar conjunctiva
4. Cornea

Look at the patient's face...



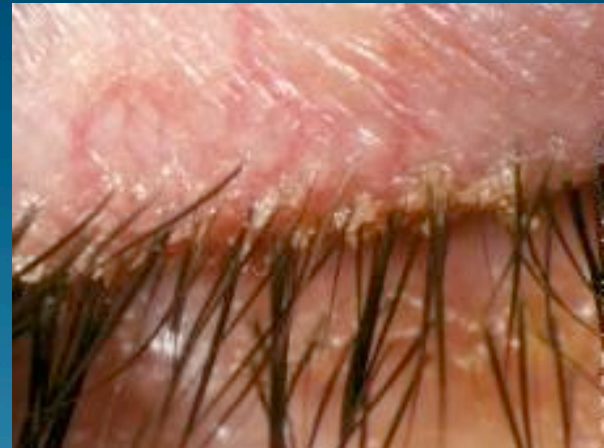Disorders of Eyelid Aperture



Lagophthalmos

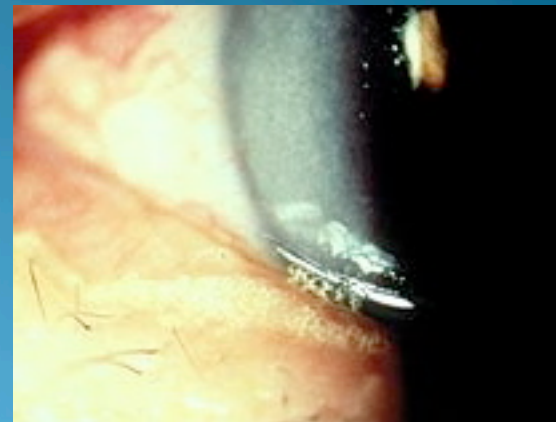
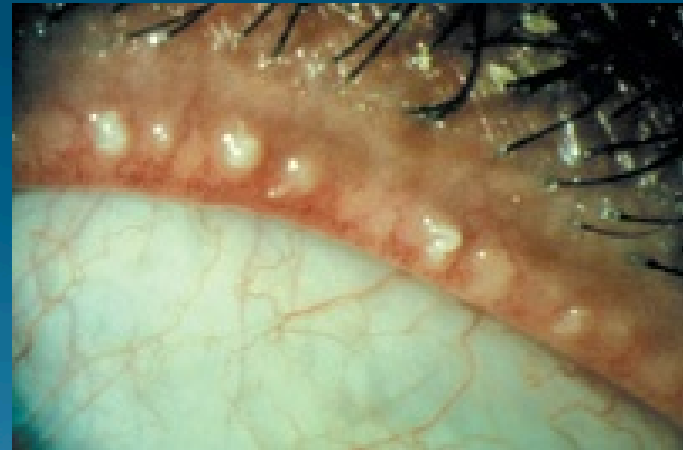Anterior Lid

- Inflammation anterior lid margin
- Crusting and debris on lids and lashes (collarettes)



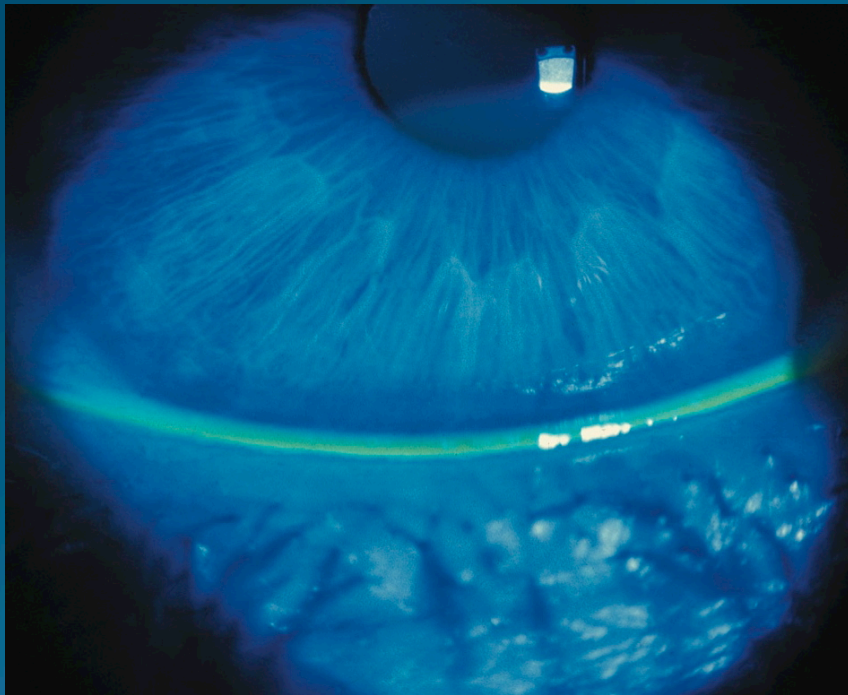
Posterior Lid

- Inflammation posterior lid margin
- Thickened meibomian gland secretions
- Telangiectatic vessels
- Soapsuds in tears

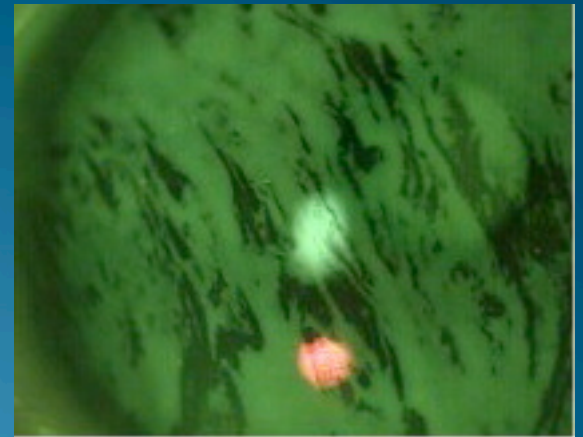


The Tear Film

- Tear meniscus



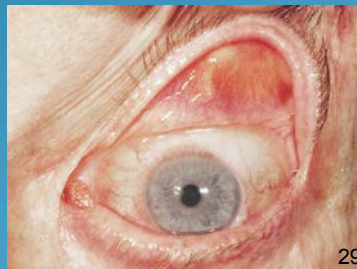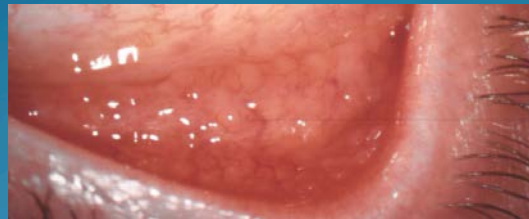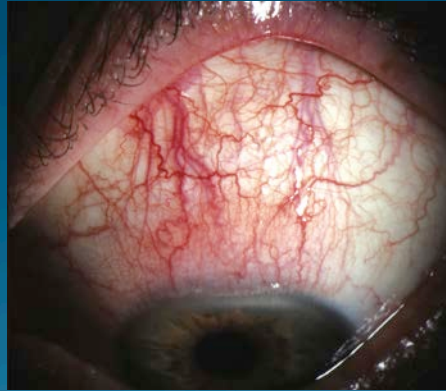- TBUT



- Schirmer's

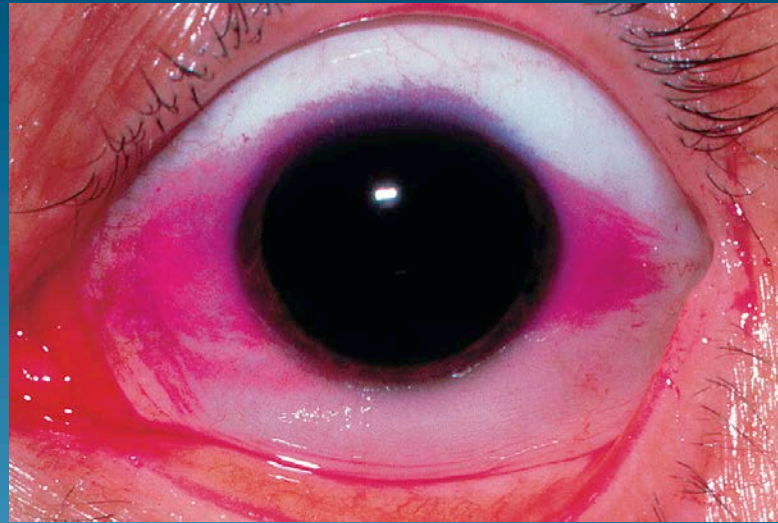
Assess the conjunctiva

- Bulbar
- Tarsal
- Flip the lid



Conjunctival Staining

- Bulbar conjunctiva
 - Flourescein
 - Rose bengal
 - Lissamine green
 - Devitalized
 - Loss mucin



Corneal Examination

Assess

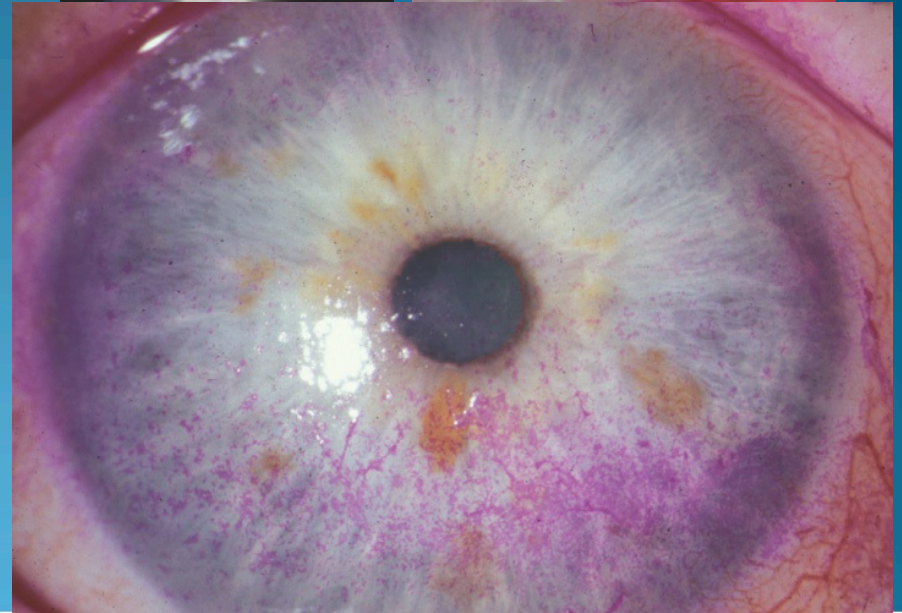
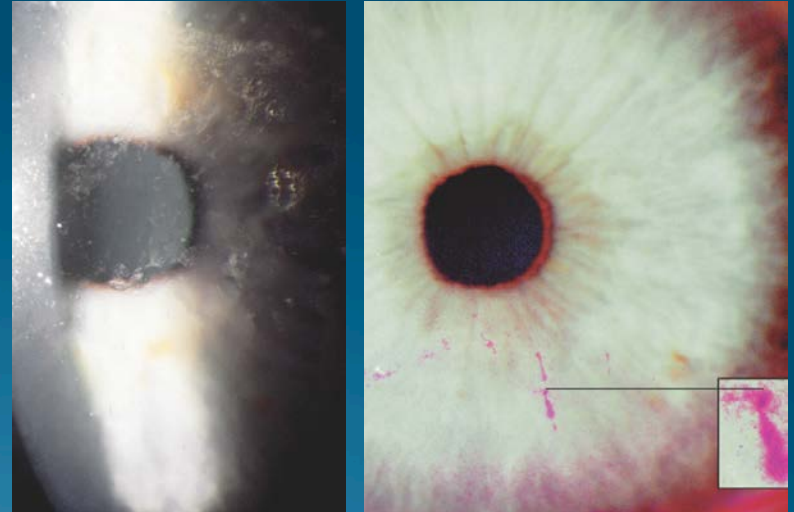
Corneal luster

Corneal sensation

Filaments

Vascularization

Infiltrates/opacities



Definition of Dry Eye

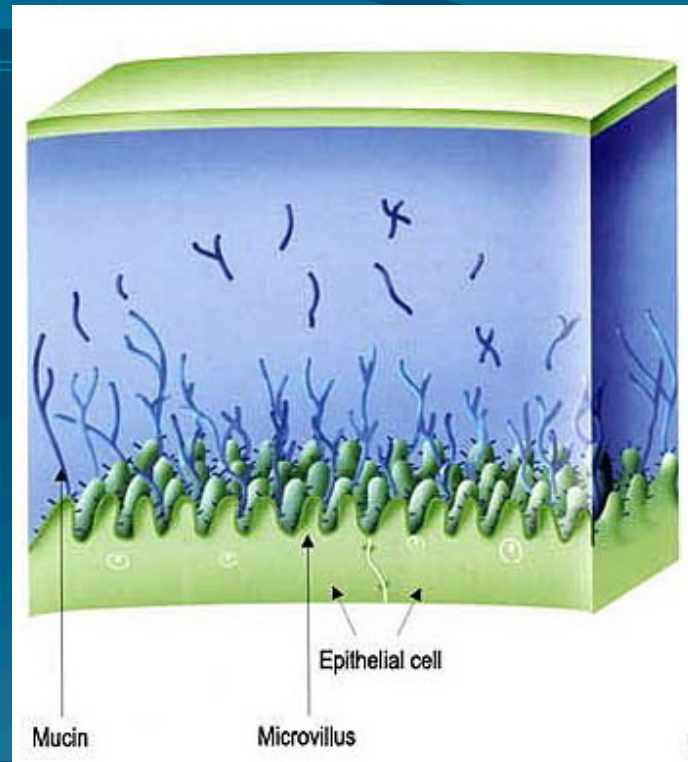
2007 DEWS (Dry Eye Workshop)

- Developed the concept of DTS
- Guidelines for diagnosis, staging and treatment

2007 Updated definition was produced:

Dry eye is a multifactorial disease of the tears and ocular surface that results in symptoms of discomfort, visual disturbance, and tear film instability with potential damage to the ocular surface. It is accompanied by increased osmolarity of the tear film and inflammation of the ocular surface.

Tear Film



Tear layer	Origin	Components	Functions
Lipid layer	Meibomian glands	Wax, cholesterol, fatty acids	Lubrication, prevent evaporation
Aqueous layer	Lacrimal gland and accessory lacrimal glands	Electrolytes, proteins, cytokines, glucose and vitamins	Lubrication, antimicrobial, O ₂ supply
Mucous layer	Conjunctival goblet cells, epithelial cells	Sulfomucin, cyalomucin, other mucins	Lower surface tension, stabilization of aqueous layer

Etiology

Aqueous Deficiency State

- Sjogren's Syndrome
- Non-Sjogren's Syndrome
 - Lacrimal gland deficiency
 - Reflex hyposecretion
 - Neurotrophic
 - LASIK
 - DM
 - Systemic medications

Evaporative State

- Intrinsic Causes
 - Meibomian gland disease
 - Low blink rate
 - Disorders of eyelid aperture and globe congruity
- Extrinsic Causes
 - Topical drops (preservatives)
 - CL
 - Allergies

In practice 2/3 of patients present with both forms of the disease

Ocular surface inflammation and increased tear film osmolarity, is the hallmark of dry eyes.

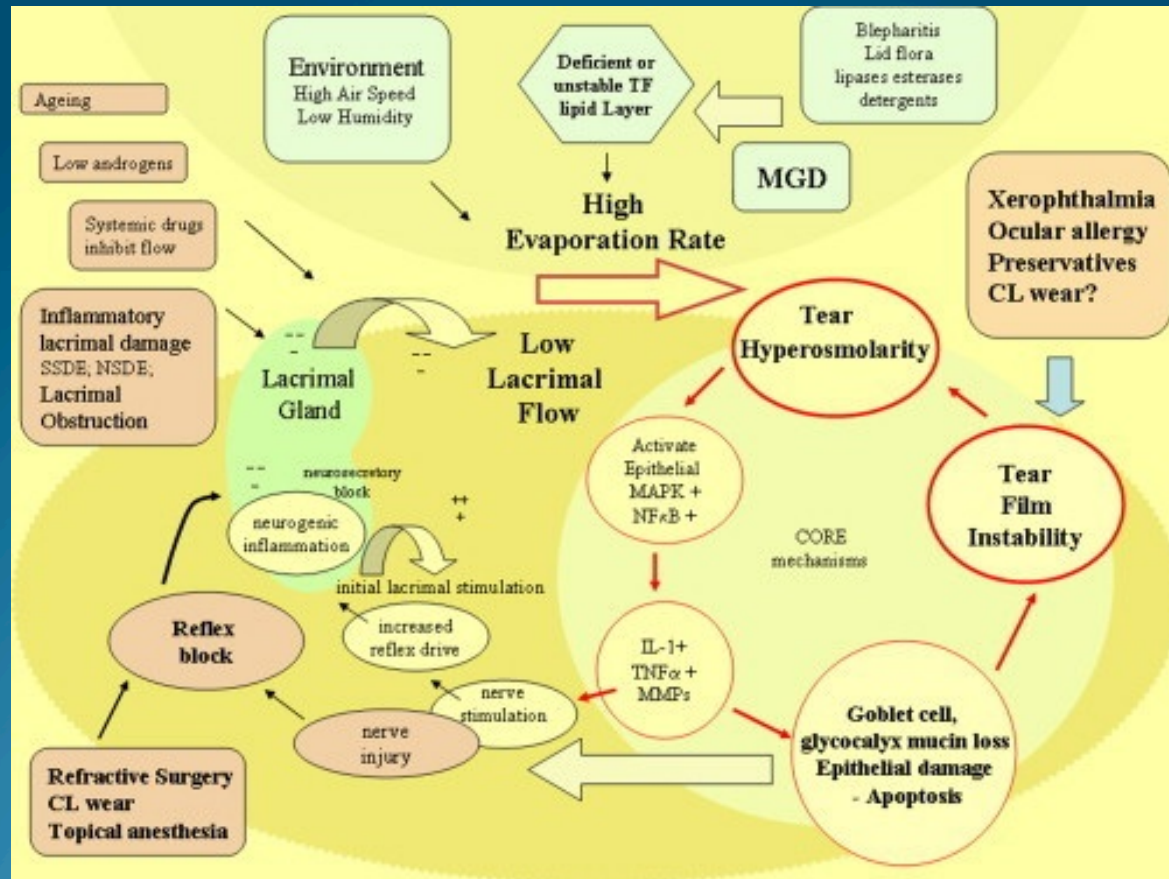


Table I

The DEWS Report used the Dephi Panel's 4-level stratification of dry eye disease based on severity of signs and symptoms

Dry Eye Severity Level	1	2	3	4*
Discomfort, severity & frequency	Mild and/or episodic; occurs under environmental stress	Moderate episodic or chronic, stress or no stress	Severe frequent or constant without stress	Severe and/or disabling and constant
Visual symptoms	None or episodic mild fatigue	Annoying and/or activity-limiting episodic	Annoying, chronic and/or constant, limiting activity	Constant and/or possibly disabling
Conjunctival injection	None to mild	None to mild	+ / -	+ / + +
Conjunctival staining	None to mild	Variable	Moderate to marked	Marked
Corneal staining (severity / location)	None to mild	Variable	Marked central	Severe punctate erosions
Corneal / tear signs	None to mild	Mild debris, ↓ meniscus	Flamentary keratitis, mucus clumping, ↑ tear debris	Filamentary keratitis, mucus clumping, ↑ tear debris, ulceration
Lid / meibomian glands	MGD variably present	MGD variably present	Frequent	Trichiasis, keratinization, symblepharon
TFBUT (sec)	Variable	≤ 10	≤ 5	Immediate
Schirmer score (mm/5min)	Variable	≤ 10	≤ 5	≤ 2

Level 1

Severity Level

- Mild discomfort
- Occasional visual symptoms
- Mild or no conjunctival signs
- Mild or no corneal signs
- Variable TBUT/Schirmer's

Treatment

- Education and enviromental modifications
- Elimination of offending systemic or topical medications
- Preserved artificial tears, gels and ung
- Eyelid therapy

Level 2

Severity Level

- Moderate discomfort
- Frequent visual symptoms
- Mild conjunctival injection
- Variable corneal staining
- Decreased meniscus
- TBUT <10sec
- Schirmer's <10mm/5min

If level I treatment inadequate Add:

- Non-preserved artificial tears
- Anti-inflammatory agents
 - Topical corticosteroids
 - Topical cyclosporin
 - Omega-3 fatty acids
- Tetracyclines (meibomianitis, rosacea)
- Punctal plugs (after control of inflammation)
- Secretagogues

Anti-inflammatory Therapy

- **Topical steroids**

- Immediate anti-inflammatory effect
- Short term pulses QID for 2-3 weeks
- Can combine with other treatments
- Loteprednol (Lotemax), flourometholone (Flarex/FML), prednisolone (Predforte)

Cyclosporin A 0.05% (Restasis)

- Inhibits the action of T-lymphocytes
- 3 weeks to 3 months for noticeable effect
- Prescribed BID for 6-12 months or longer
- Can cause burning if significant superficial keratitis
- Can be useful for the treatment of posterior blepharitis
- Can improve outcomes after LASIK

*Safety and efficacy of cyclosporin 0.05% drops vs artificial tears in dry eye patients having LASIK. Journal of Cataract and Refractive Surg 2006.

Does it work?

- 75% clinical improvement
- Decreased symptoms, corneal and conjunctival staining
- 59% increased Schirmer testing

Lifitegrast

- LFA-1 antagonist that prevents T-cell mediated release of inflammatory cytokines
- In clinical trials it significantly improved clinical signs and symptoms of dry eyes.
- Can begin to exert effect in 2 weeks

Omega-3 essential fatty acids (fish and/or flaxseed oil)

- Decrease inflammation
- Improvement in dry eye signs and symptoms*
 - Dry Eye Formulations
 - Thera Tears Nutrition
 - Tears Again Hydrate

*Barbino, et al. Cornea 2003;22:97-101

*Rashid et al. Topical omega 3 and omega 6 fatty acids for the treatment of dry eye. Arch Ophthalmol 2008.

Tetracyclines

- **Anti-inflammatory**
 - Decrease activity of collagenase, phospholipase A₂, MMP, IL-1 and TNF-alpha
 - Inhibition of lipase (decrease FFA-destabilize tear film and cause inflammation)
- **Anti-angiogenic effect**
- **Antibiotic effect**
 - Doxycycline 20-100 mg /day
 - Periostat (20mg)
 - Alodox kit (20mg doxy + Ocusoft lid scrub + foam)
 - Minocycline 50-100mg/day
 - Tetracycline

Level 3

Severity level

- Discomfort severe or constant
- Visual symptoms constant
- Conjunctival staining moderate to marked
- Corneal staining marked-central
- Tear signs: Filaments
- TBUT <5sec
- Schirmer's <5 mm

Treatment- add

- Permanent punctal occlusion
- Autologous serum
- Contact lenses
- Mucomyst

Level 4

Severity level

- Discomfort severe/disabling
- Visual symptoms-constant
- Marked conjunctival injection and staining
- Severe corneal staining
- Filaments, mucous clumping
- Ulceration
- TBUT immediate
- Schirmer's <2mm

Treatment add

- Systemic anti-inflammatory
- Surgery
 - Tarsorrhaphy
 - Amniotic membrane
 - Salivary gland transplant

Considerations

- Aggressive therapy for ocular surface disease based on primary etiology (aqueous deficiency vs evaporative).

Anti-inflammatory medications

Omega 3 and tetracyclines

Meibomian gland expression

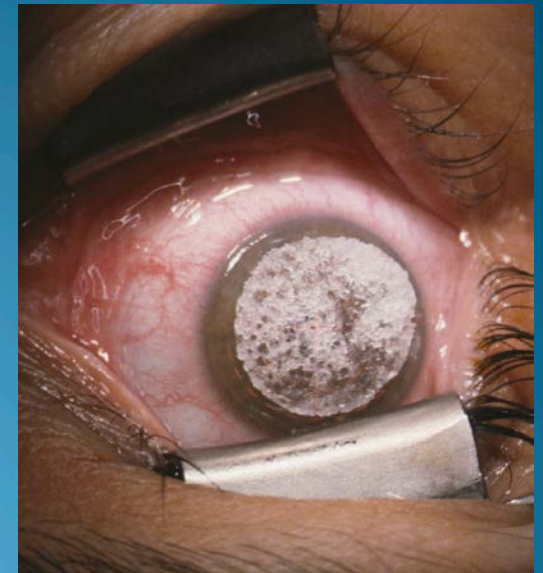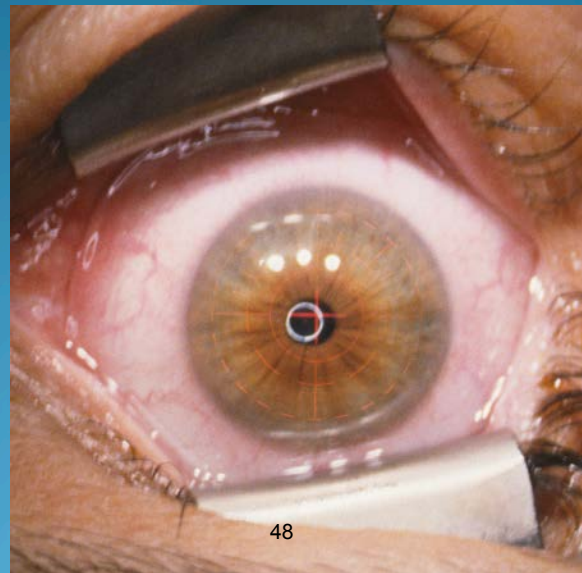
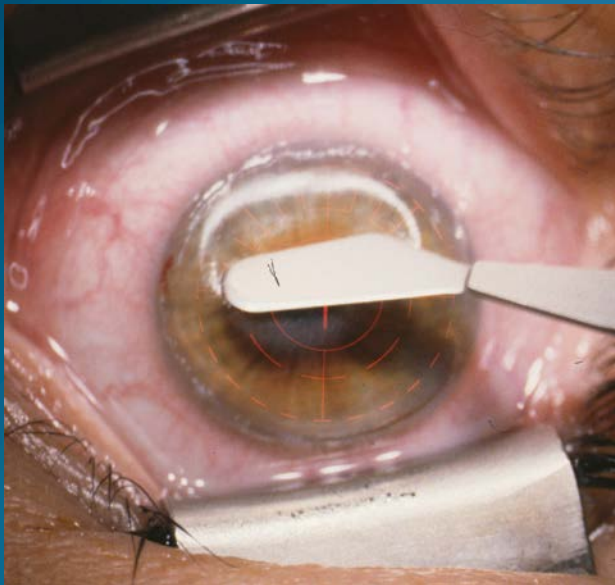
Eyelid hygiene

Punctal plugs

Amniotic membrane

Advanced Surface Ablation

It is still controversial: PRK may cause less dry eye than LASIK.



Toric IOL Preferred over LRI

Alcon does not receive or retain any patient data. Please print a copy of the final output for your records. Contact your Alcon representative for available AcrySof® Toric IOL models.

Print

Lens Recommendation

Doctor & Patient Information	
Doctor Name	Dr. Smith
Patient Information	Mr. Jones
Eye Selection	OS (Left)
Lens Details	
AcrySof® Toric IOL	SN60T4
IOL Spherical Equivalent (SE)	21.0 D
Axis of Placement	36°
IOL Cylinder (Cyl)	2.25 D
Calculation Details	
Pre-op Corneal Cylinder:	2.20 x 30°
Surgically Induced Cylinder:	0.50 x 90°
Crossed Cylinder Result (corneal plane):	2.00 x 36°
Crossed Cylinder Result (IOL plane):	2.92 x 36°

IOL: SN60T4 21.0D SE;Cyl:2.25D @ 36°
 Flat K:41.60D @ 120° Steep K:43.80D @ 30°
 P-IOL:21.0D SIC:0.50D IL:0° [V2.0.2]
 1951f1d1b1f022fcb840d017c0cb1fc3 3/2/06 18:19:55

N: Nasal T: Temporal

Pre-Op Information

Patient Data	
Flat K	41.60 D
@ Flat Meridian	120°
Steep K	43.80 D
@ Steep Meridian	30°
IOL Spherical Power (P-IOL)	21.0 D
Surgically Induced Cylinder (SIC)	0.50 D
Incision Location (IL)	0°

Flat K:41.60D @ 120° Steep K:43.80D @ 30°
 P-IOL:21.0D SIC:0.50D IL:0° [V2.0.2]
 1951f1d1b1f022fcb840d017c0cb1fc3 3/2/06 18:19:55

Steep
 Flat
 Incision

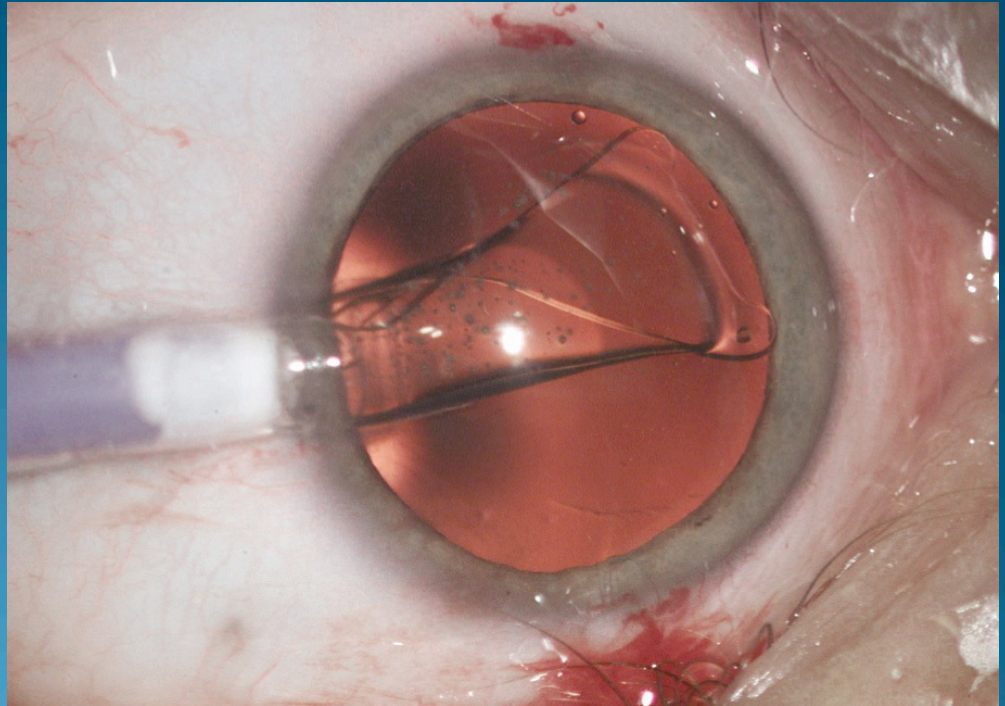
Notes:

1951f1d1b1f022fcb840d017c0cb1fc3 3/2/06 18:19:55
 V: 2.0.2

Calculator | Tutorial | Help | Privacy Policy & Legal Terms



Vision ICL



Summary

- Untreated ocular surface disease can profoundly impact surgical outcomes and patient satisfaction.
- Preexisting dry eyes needs to be treated aggressively before IOL calculations and surgery.
- Persistent dry eye following surgery is critical for successful refractive and cataract surgery.

Thank You

Patricia B. Sierra, M.D.
 1515 River Park Dr. Suite 100
 Sacramento, CA 95815
 (916) 649-1515
 patriciasierra@hotmail.com

Education	Undergraduate and Medical School (8-year program) National Autonomous University of Honduras	1988-1996
	Research Assistant Fellow Bascom Palmer Eye Institute, University of Miami, FL	1997-1998
	Internship in Internal Medicine Mercy Catholic Medical Center, Philadelphia, PA	1998-1999
	Residency in Ophthalmology Eye and Ear Institute of Pittsburgh University of Pittsburgh, Pittsburgh, PA	1999-2002
	Cornea, External Diseases, Refractive Surgery and Glaucoma Fellowship Minnesota Eye Consultants/Phillips Eye Hospital Minneapolis, MN	2002-2003
Professional Experience	Teaching Assistant of Human Anatomy National Autonomous University of Honduras	1990-1996
	Comprehensive ophthalmology, cornea and refractive surgery specialist Medical Vision Technology, Inc	9/2003 - 3/2007
	Grutzmacher, Lewis & Sierra. Surgical Eye Specialists	6/2007-present
	Associate Medical Director, Vision Service Plan (VSP)	1/2011-present
Certifications	ECFMG Certification (USMLE Steps I, II, and III)	1997
	American Board of Ophthalmology	2003
Honors/Awards	Academic Excellence in the Career of Medicine Award	1996
	Medical School Class Top Student Award	1996
Professional Organizations	American Academy of Ophthalmology American Society for Cataract and Refractive Surgery International Society of Refractive Surgery Cornea Society	
Languages	English and Spanish (Fluent)	

Publications

- LASIK. **P. Sierra**, D. Hardten, E. Davis. In: Yanoff and Duker: Ophthalmology, ed. 4. In print.
- DSAEK Pearls for Cataract Surgeons. **P. Sierra**. Cataract and Refractive Surgery Today. Jan 2009;9(1):31-34.
- LASIK. **P. Sierra Wilkinson**, D. Hardten, E. Davis. In: Yanoff and Duker: Ophthalmology, ed. 3. St. Louis: Mosby 2009.
- LASIK for Myopia. **P. Sierra Wilkinson**, D. Hardten, R. Lindstrom. In: Krachmer- Mannis-Holland: Cornea, ed.2. St. Louis: Mosby 2005.
- History of Phakic Intraocular Lenses. **P. Sierra Wilkinson**, D. Hardten. In: Lindstrom RL, Hardten DR, Davis EA: Phakic Intraocular Lenses eds. Thorophare, NJ: SLACK Incorporated 2004.
- Phakic Intraocular Lenses in Pseudophakic Patients. **P. Sierra Wilkinson**, D. Hardten. In: Lindstrom RL, Hardten DR, Davis EA: Phakic Intraocular Lenses, eds. Thorophare, NJ: SLACK Incorporated; 2004.
- Myopia, PRK, LASIK and LASEK. **P. Sierra Wilkinson**, D. Hardten, R. Lindstrom, E. Davis. In: Roy FH, Arzabe C, eds. Master Techniques in Refractive Surgery. Thorophare, NJ: SLACK Incorporated; 2004.
- Antibiotic Options Besides Vancomycin for Treating MRSA (Methicillin Resistant *Staphylococcus aureus*) Keratitis. **P. Sierra Wilkinson**, R.P. Kowalski, Y.J. Gordon. University of Pittsburgh, Pittsburgh, PA. IOVS 2001, 42(4):S254
- A Mouse Model for RPE Injury Based On Blue Light Exposure. E. Hernandez, P. Morales, **P. Sierra Wilkinson**, P. Rubsamen, K.G. Csaky, and S.W. Cousins, Bascom Palmer Eye Institute, Miami, FL. IOVS 1998, 39(4):S392

Presentations

- Herpes Simplex Keratitis. Presented at Sacramento Valley Optometric Society meeting, Sacramento, CA October 2012
- Ocular Surface Neoplasms. Presented at Sacramento Valley Optometric Society meeting, Sacramento, CA May 2012
- Endothelial Keratoplasty DSEAK. Presented at VIII Congreso Nacional de Oftalmologia, Roatan, Honduras June 2011
- Deep Anterior Lamellar Keratoplasty (DALK). Presented at VIII Congreso Nacional de Oftalmologia, Roatan, Honduras June 2011

Pterygium Surgery with Fibrin Glue. Presented at VIII Congreso Nacional de Oftalmologia, Roatan, Honduras June 2011

Fungal Keratitis, New Treatments. Presented at VIII Congreso Nacional de Oftalmologia, Roatan, Honduras June 2011

Ocular Corticosteroids, the Good, the Bad and the Ugly. Presented at Sacramento Valley 23rd Ocular Symposium, Sacramento, CA March 2010.

Surgical Treatment of Keratoconus and Keratectasia. Presented at Sacramento Valley Optometric Society meeting, Sacramento, CA October 2009

Pterygium, Surgical Management. Presented at Sacramento Valley Optometric Society meeting. Sacramento, CA November 2007

Management of Recurrent Epithelial Ingrowth Following LASIK with Fibrin Glue. P. Sierra Wilkinson, N. Anderson, D. Hardten. Presented at ASCRS Meeting, April 2003, San Francisco, CA.

Variability in the Size and Regularity of the Steepened Cornea after Conductive Keratoplasty and Hyperopic LASIK. **P. Sierra Wilkinson**, A. Lombardo, J. DeMarchi, D. Hardten. Presented at ISRS Meeting, October, 2002 Orlando, FL

Reasearch Experience

Subinvestigator FDA phase 3 clinical trial: Bandage Contact Lens after Cataract Surgery. Protocol ITX-08-002. Phase 3, Sacramento, CA, 2010.

Subinvestigator, FDA phase 3 clinical trial: Artisan Phakic Intraocular Lens. Principal Investigator: David Hardten, MD. Minneapolis, Minnesota 2002-2003.

Subinvestigator, FDA phase 3 clinical trial: Visian, Implantable Contact Lens (phakic intraocular lens). Principal Investigator: David Hardten, MD. Minneapolis, Minnesota 2002-2003.

Research Assistant Fellow 1997-1998
Bascom Palmer Eye Institute, University of Miami, FL

Dry Eyes: An Immune Mediated Ocular Surface Disease

Samuel H. Lee, MD

Summary:

Dry Eye Disease is an inflammatory-mediated disease which requires targeting of the underlying inflammation to help signs and symptoms. The tear film is an integral component of the ocular surface which helps transport inflammatory mediators, and is made up of multiple components which contribute to a healthy ocular surface.

T-cells are the primary cells involved in the inflammatory cascade associated with dry eye disease. Various drugs work to help reduce the T-cell mediated cascade by reducing the binding and activation of T-cells to their adhesion molecules. There are multiple drugs on the market and on the horizon that will be targeting this inflammatory cascade to help treat ocular surface disease.\

Dry Eyes: An Immune Mediated Ocular Surface Disease

Samuel H. Lee, MD

Objectives

At the conclusion of this presentation, participants should be able to:

- Understand the tear film
- Understand the role of inflammation in ocular surface disease (OSD)
- Be familiar with what tools we have to combat OSD

I. Tear Film

Summary of the function and composition of a healthy tear film

II. Inflammation and OSD

T-cell mediated inflammatory disease

How T- cells play a role

IV. Therapy for OSD

Tears, compresses, punctal occlusion

Immunosuppressants and immunomodulators

V. On the horizon

Dry eye treatment options coming in the future

Dry Eyes: An Immune Mediated Ocular Surface Disease

Samuel Lee, MD

Sacramento Eye Consultants

2016 Fall Optometric Continuing Education Seminar

November 1, 2016

Financial Disclosures

■ None

Objectives

- Understand the tear film
- Understand the role of inflammation in ocular surface disease
- Be familiar with what tools we have, and what tools are on the horizon, to combat OSD

Functions of a Healthy Tear Film

- Optical clarity and refractive power
- Ocular surface comfort - lubrication
- Protection from environmental and infectious agents

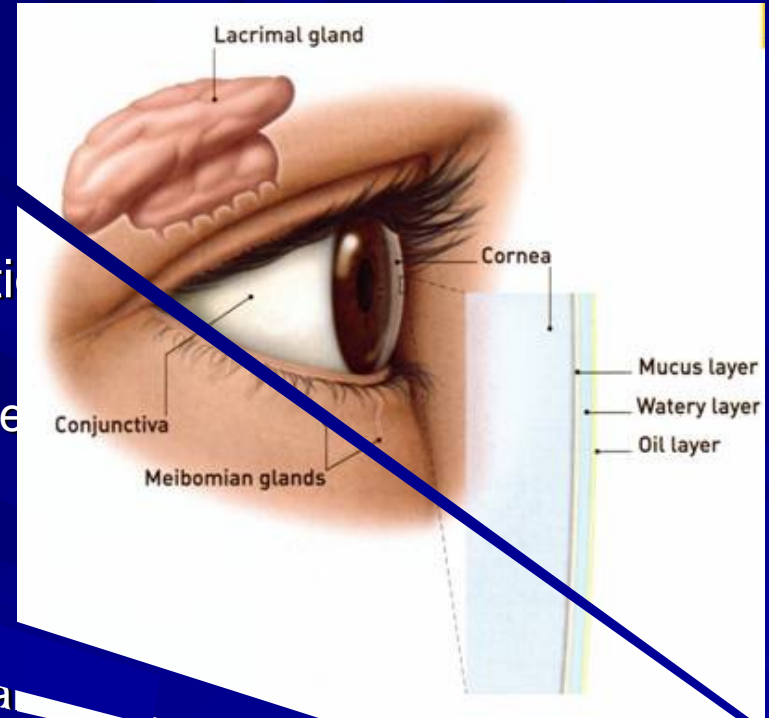
– Release of immunological proteins, antibodies, complement

– Removal of debris and away particles

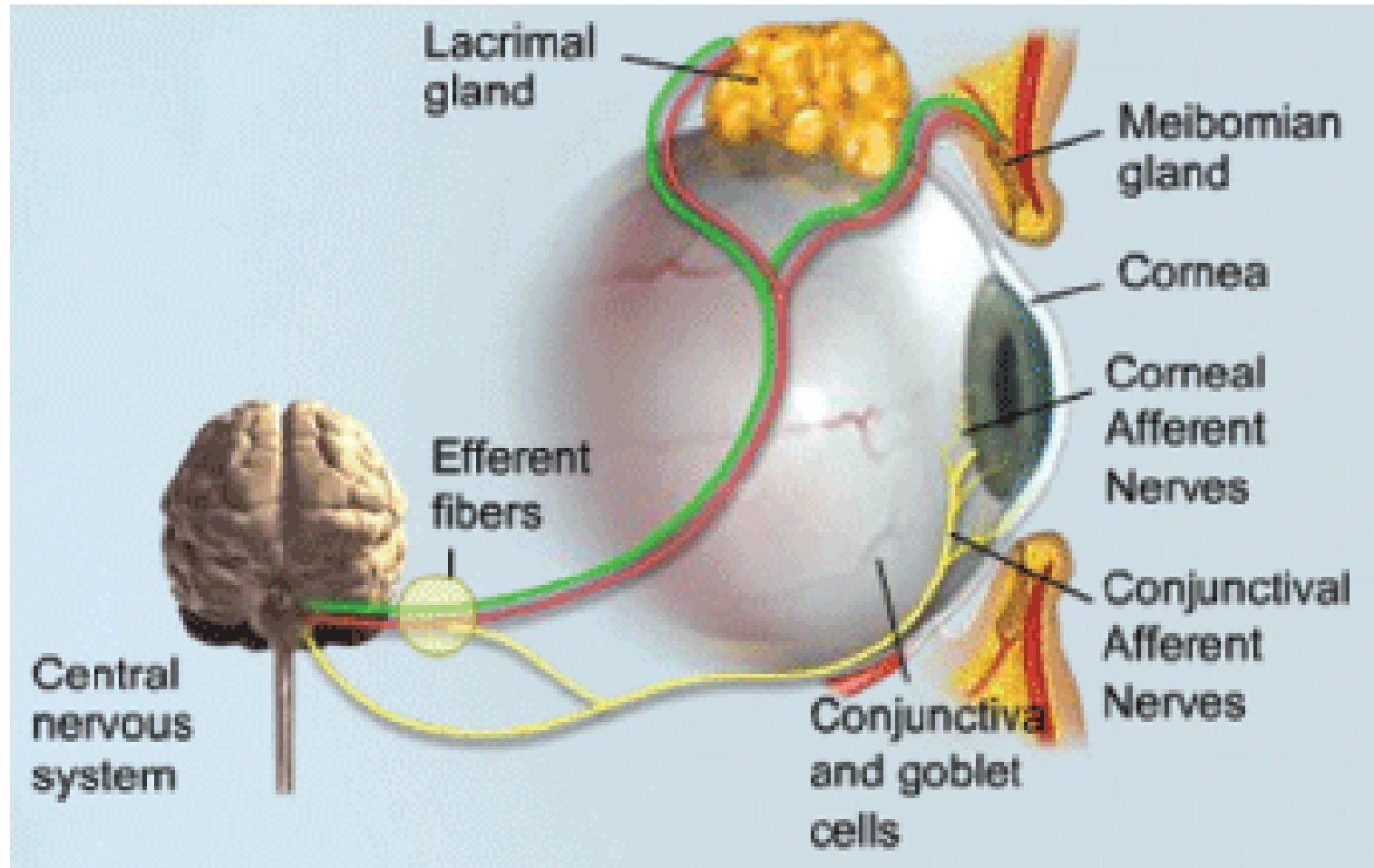
– Maintenance of corneal epithelium

– Electrostatic

– Protein factors for growth and healing



■ **Figure 1. Lacrimal Functional Unit**



The Normal Tear Film: 3 Major Components


**MEIBOMIAN
GLANDS**

Lipid Layer

**LACRIMAL
GLAND**

Aqueous/
Mucin Gel

**GOBLET
CELLS**



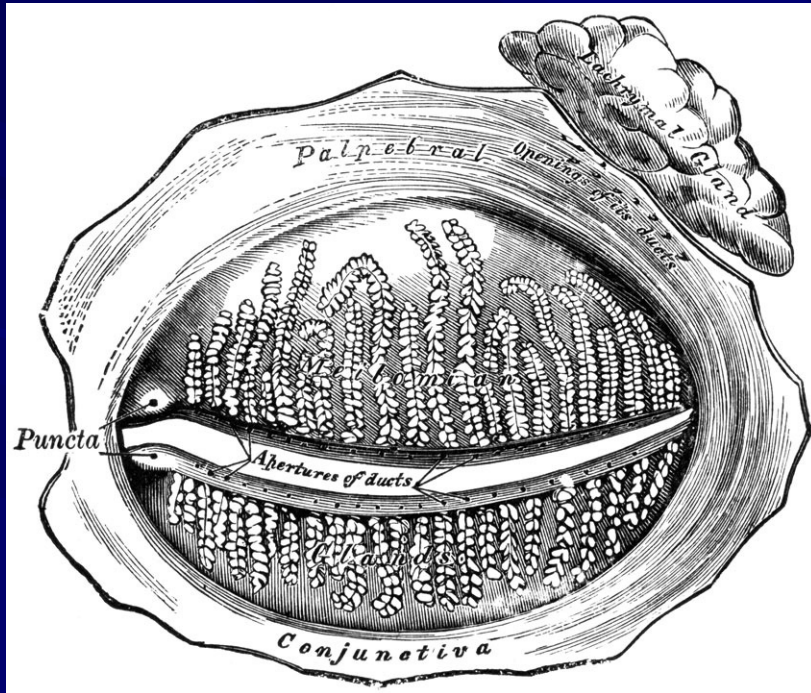
← Soluble Proteins

← Soluble Mucins

← Membrane Mucins

← Epithelium

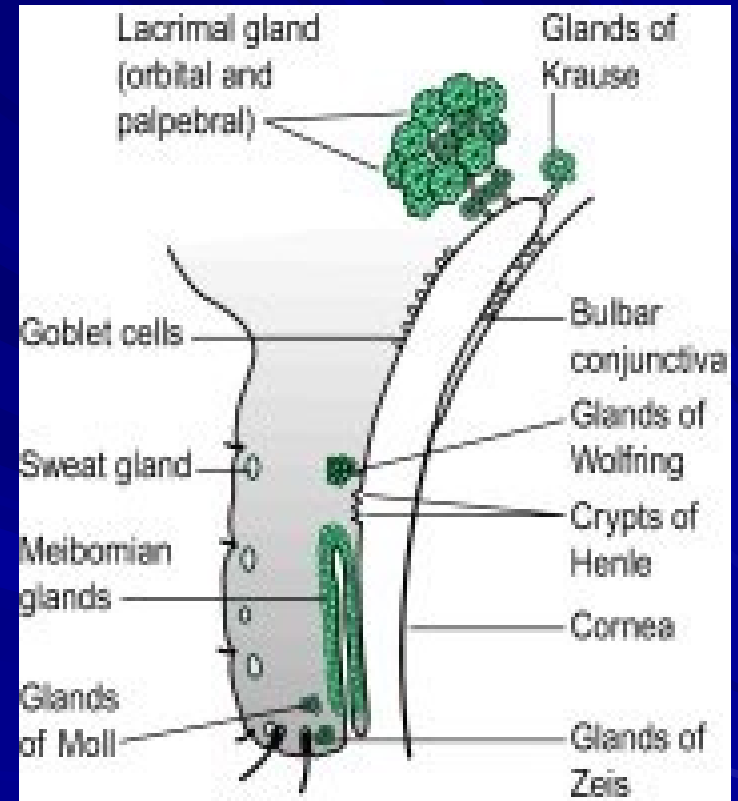
1. Lipid Secretion: Meibomian Glands



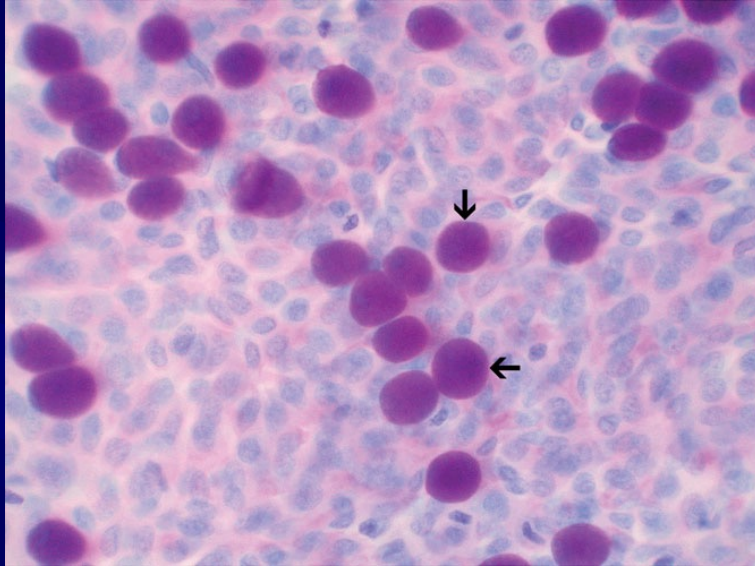
- The lipid layer restricts evaporation to 5-10% of tear flow
 - Also helps lubricate

2. Aqueous Secretion: Lacrimal Glands

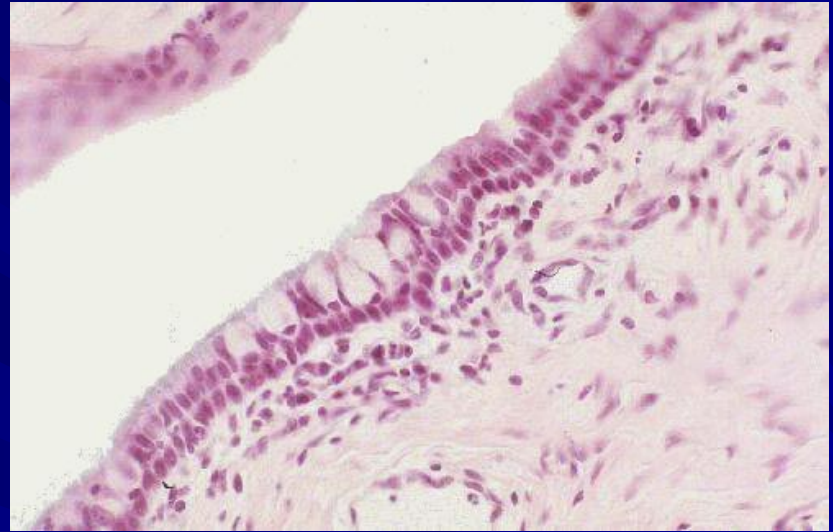
- Lacrimal glands secrete:
 - Aqueous component
 - Most tear proteins
- Basal tear secretion: glands of Krause and Wolfring (accessory)
- Reflex tearing: main lacrimal gland



3. Mucin Secretion: Goblet Cells



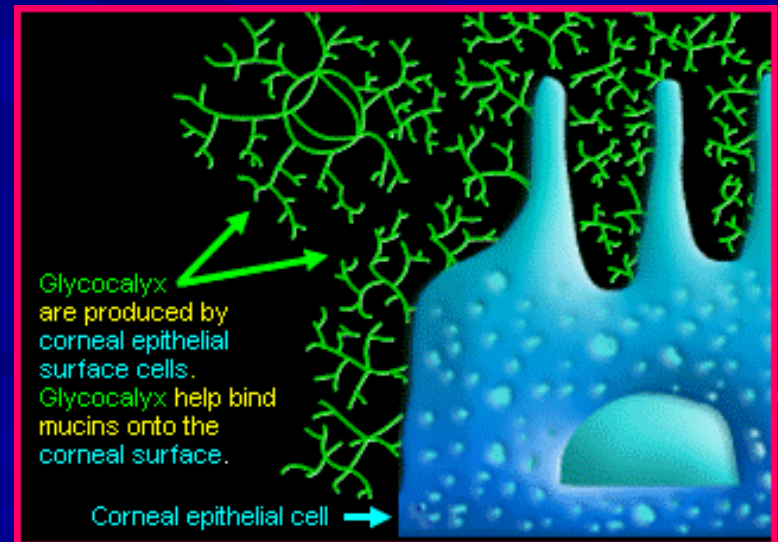
Goblet cells secreting mucins (arrows)
surrounded by epithelial cells



- Secretory: 5-20% of conjunctival epithelial cells are mucin-producing goblet cells
- Soluble mucins - essential for viscosity of the normal tear film
 - Helps resist thin spots and tear break-up

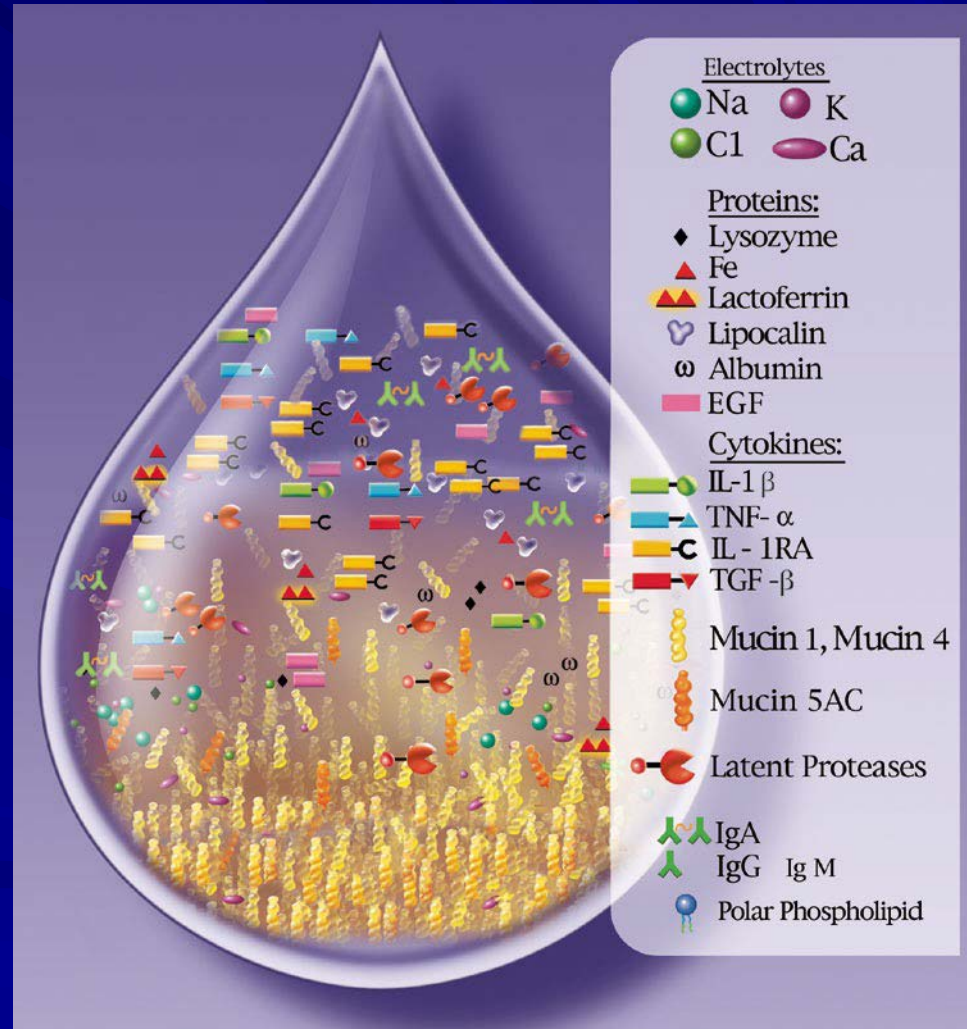
Mucins

- Mucin layer converts the corneal epithelial surface from hydrophobic to hydrophilic
- Thickness 20-50 nm
- Large carbohydrate side chains Three subtypes:
 - Secretory: **MUC5AC**
 - Soluble: MUC7
 - Membrane bound: MUC1 → Glycocalyx



Healthy Tears

- A **complex mixture** of proteins, mucin, and electrolytes
- Antimicrobial proteins: Lysozyme, lactoferrin, sIgA
- Growth factors & suppressors of inflammation: EGF, IL-1RA
- Soluble mucin 5AC secreted by goblet cells provides viscosity
 - Membrane-bound mucins 1 & 4 help stabilize tear film
- Electrolytes for proper osmolarity



Inflammation and OSD

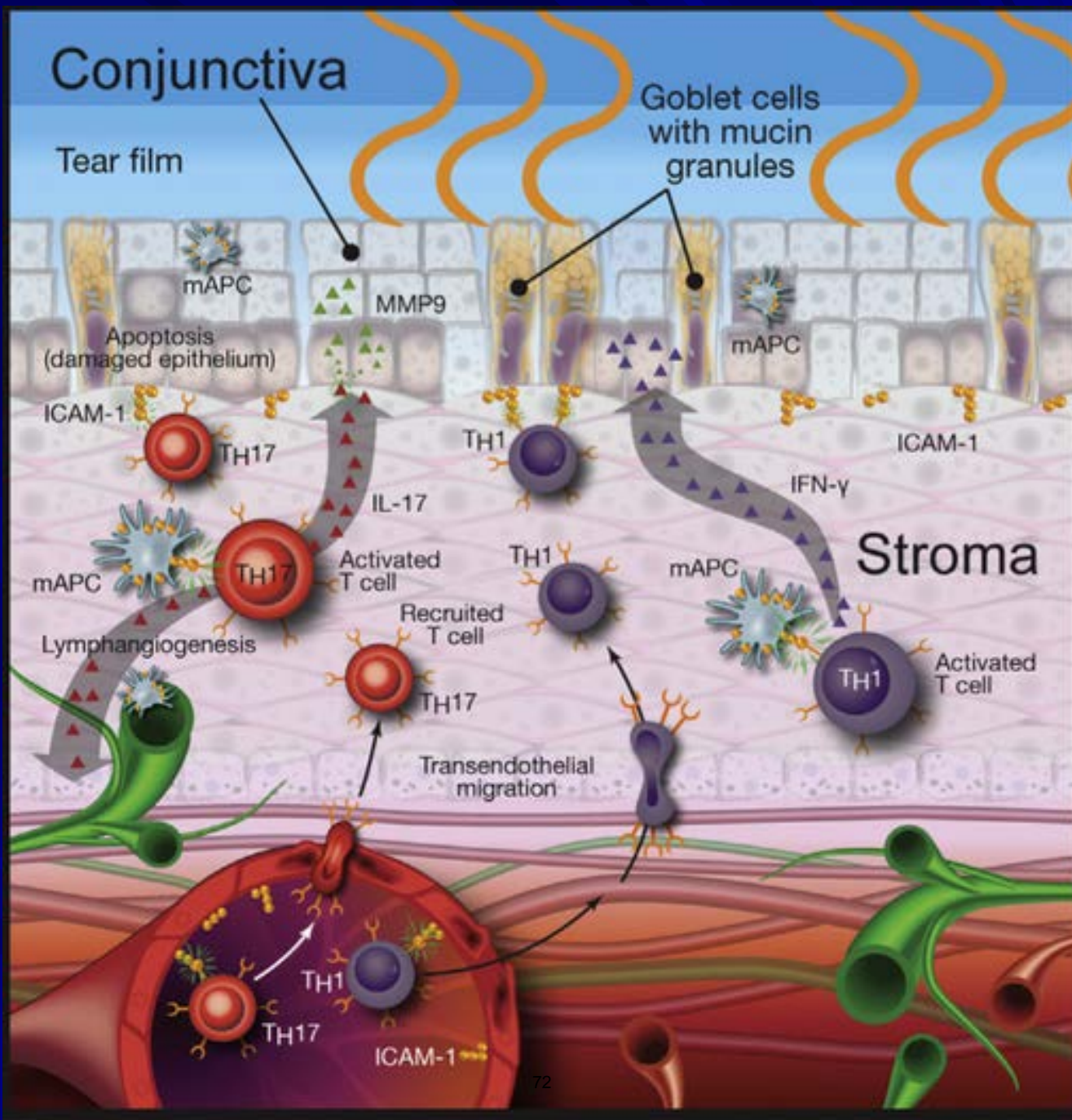
- Growing body of evidence to show that Ocular Surface Disease is a T-cell mediated inflammatory disease
 - Antigens are taken into the tissue via antigen-presenting cells
 - T cells are primed by the APCs
 - T cells migrate to conjunctiva from blood vessels
 - T cells are activated

Inflammation and OSD

- Ocular surface dryness leads to release of pro-inflammatory cytokines (IL-1 and TNF- α)
- APCs are activated which trigger T cells where further cytokines are produced

T-Cells and OSD

- CD4+ T cells are the primary inflammatory cells involved in OSD
 - Differentiate into Th1 and Th17 cells which then migrate to ocular surface and release cytokines which promote pro inflammatory mediators (MMP, chemokines, cytokines)
 - This inflammatory cascade causes epithelial cell apoptosis and goblet cell death, as well as breakdown of the epithelial barrier



Therapy for OSD

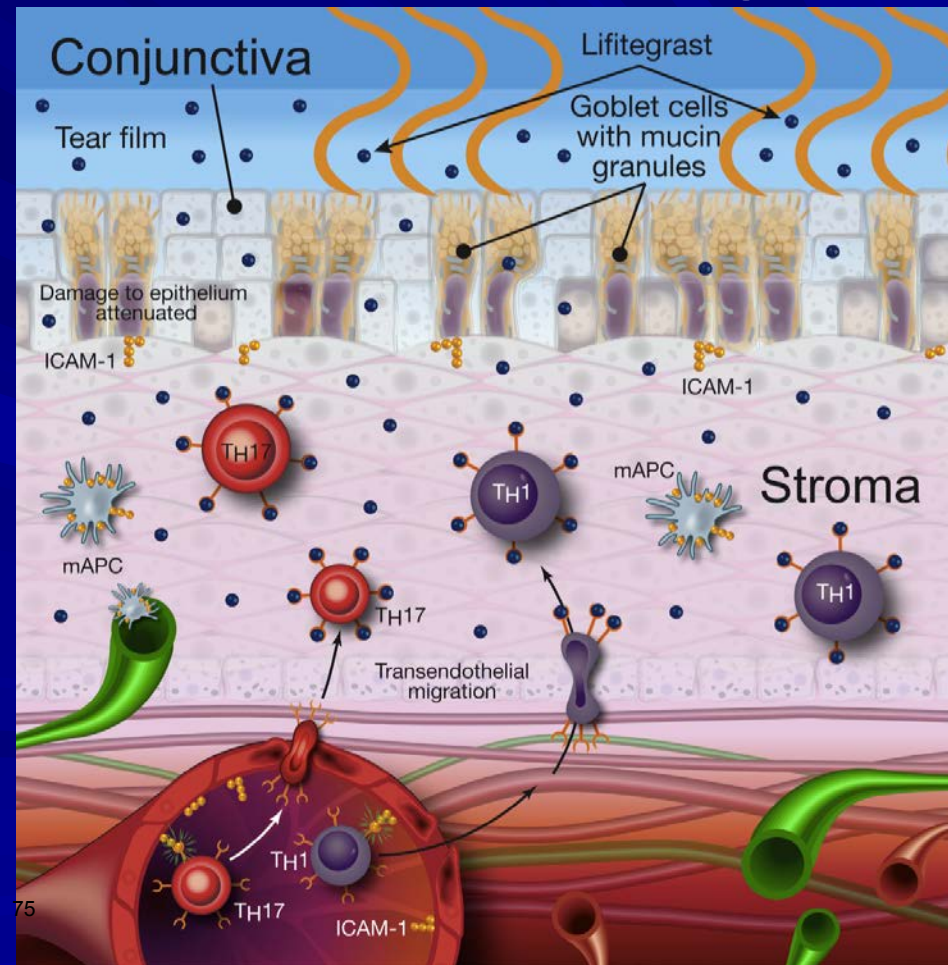
- Artificial tears
 - Helps dilute ocular surface, reduces hyperosmolarity
- Warm compresses
 - Helps encourage stabilization of tears by increasing oil supply from meibomium glands
- Punctal occlusion
 - Used to increase tear lake

Therapy for OSD

- Topical steroids
 - Gold standard is preservative-free methylprednisolone
 - Helps downregulate I-CAM and also reduces inflammatory cell density
- Cyclosporine and Tacrolimus
 - Helps downregulate I-CAM

Lifitegrast

- Binds to ICAM-1 to help prevent binding of LFA-1 to ICAM-1



On the horizon...

The Dry-Eye Pipeline

Molecule	Company	Mechanism of Action	Status
Cyclokat	Santen	Immunosuppressive	Phase III/ Recommended for approval by EMA
Lifitegrast	Shire	LFA-1 antagonist	Phase III
MIM-D3	Mimetogen	Selective TrkA receptor agonist	Phase III
SI-614	Seikagaku	Modified hyaluronate	Phase III
SkQ1	Mitotech	Mitochondria-targeted antioxidant	Phase II/III
RGN-259	ReGenTree	Thymosin beta-4	Phase II/III
Intranasal neurostimulatory device	Oculeve-Allergan	Tear stimulation	Phase II/III
EBI-005	Eleven Biotherapeutics	IL-1 antagonist	Phase III
Cis-UCA	Herantis	Anti-inflammatory; cytoprotective effect in response to UVB stress	Phase II
CycloASol	Novaliq	Immunosuppressive	Phase II
Cross-linked hyaluronic acid	Jade Pharmaceuticals	Modified hyaluronate barrier function, enhanced dwell time	Phase II

References

- Stern ME, Schaumburg CS, Pflugfelder SC. Dry eye as a mucosal auto- immune disease. *Int Rev Immunol* 2013;32:19-41
- Stern ME, Gao J, Morgan GA, et al. The role of ICAM-1 as a signal pro- tein for predisposition of ocular surface inflammation. *Adv Exp Med Biol* 2002;506(Pt B):753-9
- Pflugfelder SC. Antiinflammatory therapy for dry eye. *Am J Ophthalmol.* 2004;137(2):337–342. doi: 10.1016/j.ajo.2003.10.036.
- AAO Cornea/External Disease PPP Panel. Preferred Practice Pattern guidelines. Dry eye syndrome. San Francisco, CA, American Academy of Ophthalmology. Available at: <http://www.aao.org/preferred-practice-pattern/dry-eye-syndrome-ppp-2013>; 2013
- Stevenson W, Chauhan SK, Dana R. Dry eye disease: an immune-mediated ocular surface disorder. *Arch Ophthalmol* 2012;130:90-100
- Sheppard JD, Torkildsen GL, Lonsdale JD, et al, OPUS-1 Study Group. Lifitegrast ophthalmic solution 5.0% for treatment of dry eye disease: results of the OPUS-1 phase 3 study. *Ophthalmology* 2014;121:475-83
- Tauber J, Karpecki P, Latkany R, et al, OPUS-2 Investigators. Lifitegrast ophthalmic solution 5.0% versus placebo for treatment of dry eye disease: results of the randomized phase III OPUS-2 study. *Ophthalmology* 2015;122:2423-31
- Perez V, Pflugfelder S, Zhang S, et al, Lifitegrast, a Novel Integrin Antagonist for Treatment of Dry Eye Disease. *The Ocular Surface*. April 2016. Volume 14, Issue 2, Pages 207–215

SAMUEL HYUNG LEE

3555 Las Pasas Way
 Sacramento, CA 95864
 Cell: (408) 309-9338
 Office: (916) 614-4360
 samuel.lee.md@gmail.com

Current Position

August 2013-Current

Participant Physician – Cornea
 The Permanente Medical Group
 Kaiser Permanente Point West
 Sacramento, CA

Education and Training

July 2012-June 2013

Cornea and Refractive Surgery Fellowship
 Illinois Eye and Ear Infirmary
 Chicago, IL

July 2009-June 2012

Ophthalmology Residency
 University of California, Davis Eye Center
 Sacramento, CA

July 2008-June 2009

Transitional Year
 Arrowhead Regional Medical Center
 Colton, CA

August 2004-June 2008

Doctor of Medicine
 AOA
 Loma Linda University School of Medicine
 Loma Linda, CA

September 2001-June 2004

Bachelor of Science in Biology
Magna Cum Laude
 Pacific Union College
 Angwin, CA

September 2000-June 2001

Biology Major
 University of California, San Diego
 La Jolla, CA

Licensure and Certification

March 2010-Present	California State Board License A110394
March 2010-Present	Federal DEA Certificate FL1781308

Honors and Achievements

April 2008	Best Paper of Session (BPOS) Winner <i>Keratorefractive Surgery Complications</i> ASCRS 2008
May 2008	Membership <i>Alpha Omega Alpha, Epsilon Chapter</i>
September 2004	Alumni Scholarship <i>Merit based award, Loma Linda University</i>
June 2004	MFAT Award <i>Highest score Biology Major Field Assessment Test</i> Pacific Union College

Membership in Professional Organizations

2014-2016	Team Ophthalmologist <i>Sacramento Kings</i>
August 2013-Present	Cornea Society
July 2009-Present	American Academy of Ophthalmology
July 2009-Present	American Society of Cataract and Refractive Surgery

Papers, Presentations, Book Chapters

In Press	Chapter 64. <i>Infectious Disease: Corneal Manifestations.</i> Samuel H. Lee, MD, Ivan R. Schwab, MD. In: Krachmer-Mannis-Holland: Cornea, ed. 4
----------	--

- April 2015 *Difficult and Complicated Cases in Refractive Surgery.*
Chapter 26: Limitations of Reorientation of a LASIK
Free Cap. Chapter 42: Management of Traumatic
LASIK Flap Edge Invagination. Chapter 52:
Corneal Ectasia: Management of Corneal Ectasia
After LASIK with Deep Anterior Lamellar
Keratoplasty (DALK) and Transepithelial
Photorefractive keratectomy (PRK) with Mitomycin
C. Editors: Jorge L. Alio, Dimitri T. Azar
- June 2014 Jain S, Patel RM, Hage Z, Lim J, Lee S, Amin-
Hanjani S, Setabutr P, Aakalu VK. Cerebrospinal
Fluid Leak Presenting as Epiphora. *Ophthal Plas
Reconstr Surg.* 2014 June 6
- April 2014 *Keratoprotheses and Artificial Corneas.* Chapter 2:
History of the Artificial Cornea. Editors: M.
Soledad Cortina, Jose de la Cruz.
- December 2013 Lee SH, Mannis MJ, Shapiro B, Li JY, Polage C,
Smith W. Evaluation of microbial flora in eyes with
a Boston type 1 Keratoprosthesis. *Cornea.* 2013
Dec;32(12):1537-9
- May 2012 The Association for Research in Vision and
Ophthalmology Annual Meeting
Fort Lauderdale, FL
Poster Presentation: Evaluation of the microbial
flora in patients with a Boston Type 1
Keratoprosthesis

Mentor: Mark J. Mannis, M.D.
- May 2011 UC Davis Eye Center Symposium
Napa, CA
Oral presentation: Etiology of the Hyperopic Shift
in Stage 4 Diffuse Lamellar Keratitis

Mentors: Francisco Garcia-Ferrer, M.D., Brian R.
Will, M.D

- May 2011
The Association for Research in Vision and Ophthalmology Annual Meeting
Fort Lauderdale, FL
Poster Presentation: Update On Pseudophakic CME: High Resolution Insights for the Patients that do not Return to 20/20

Mentor: David G. Telander, M.D.
- April 2009
American Society of Cataract and Refractive Surgery Annual Meeting
San Francisco, CA
Course Instructor: Corneal Physiology as Related to Refractive Surgery

Mentor: Brian R. Will, M.D.
- April 2008
American Society of Cataract and Refractive Surgery Annual Meeting
Chicago, IL
Paper Presentation: Stage 4 Diffuse Lamellar Keratitis and Central Toxic Keratopathy: Causes, Management, and Pathophysiology (BPOS Winner)

Mentor: Brian R. Will, M.D.
- May 2006
The Association for Research in Vision and Ophthalmology Meeting
Fort Lauderdale, FL
Poster Presentation: A 19-Year Retrospective Review of Treated Cases of Endogenous Endophthalmitis

Mentor: Joseph T. Fan, M.D.
- February 2006
Western Student Medical Research Forum Conference
Carmel, CA
Oral presentation: A retrospective review of the prognosis and risk factors associated with endogenous endophthalmitis

Mentor: Joseph T. Fan, M.D.

Special Skills and Extracurricular Activities

Languages: Korean and Spanish

Hobbies: High performance driving and track days
Violin

Ocular Surface Disease due to Glaucoma Medications
Jacob W. Brubaker, MD

Summary:

Patients with glaucoma often require multiple eye drops to control their IOP. The preservatives can often cause toxicity and other ocular surface complications. These include allergies and overall intolerance to the drops. BAK is a common preservative leading to these problems. Several strategies can be employed in these circumstances. Drops that are BAK free as well as preservative free options can help to improve tolerance as well as control IOP.

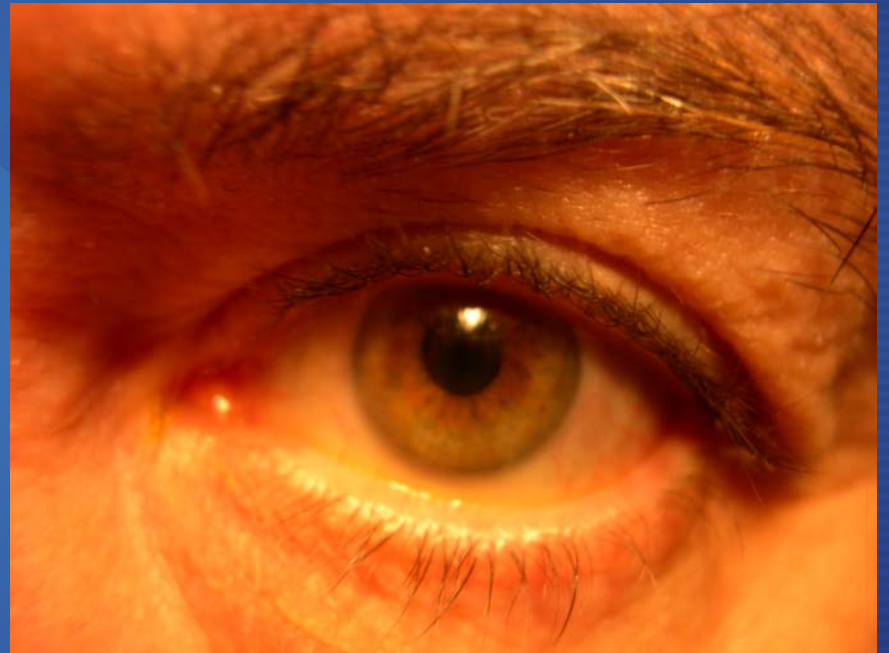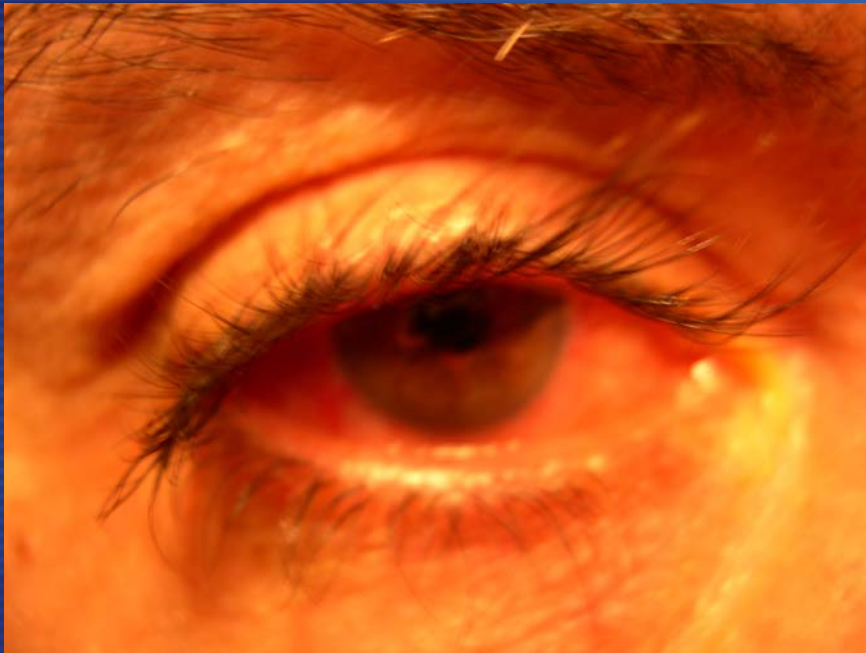This lecture will discuss the potential harmful effects preservatives and other agents in glaucoma drops. We will also discuss strategies to improve the ocular surface by avoiding potentially harmful preservatives. Finally we will discuss the future directions of glaucoma care that will include long acting drugs delivered directly to the source that will avoid ocular surface issues all together.

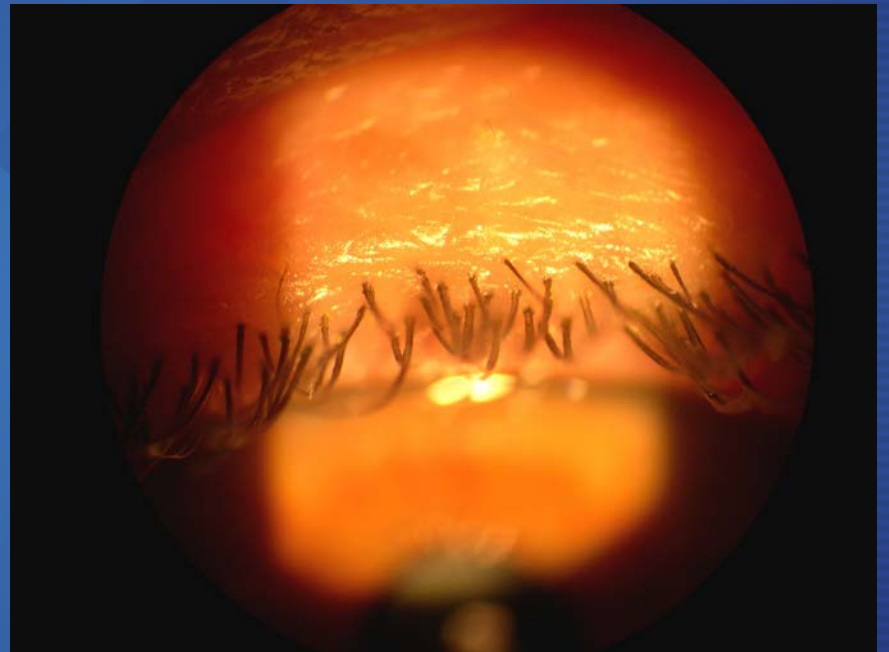
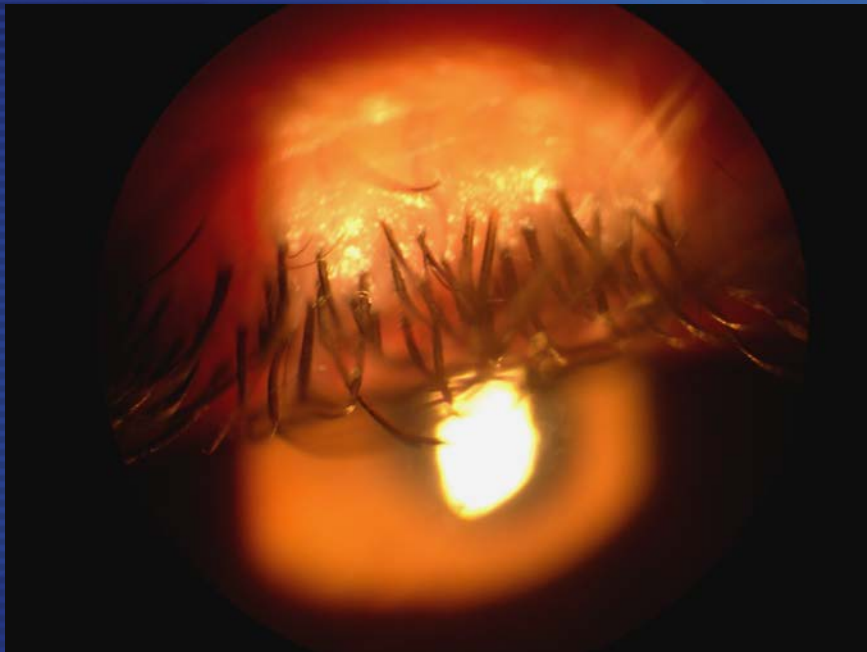
- **Ocular Surface Disease due to Glaucoma Medications**
 - **Jacob Brubaker, MD**
 - **Case Report**
 - **Dry eyes due to glaucoma drops**
 - **BAK (benzalkonium chloride)**
 - **Preservative used in over 72% of eye drops**
 - **Cationic surfactant properties (a detergent)**
 - **Preserves multi-dose containers from microbial contamination**
 - **Enhances corneal penetration of some drugs by causing epithelium separation**
 - **Effect of Preservatives in Eye Drops**
 - **BAK (benzalkonium chloride) is the preservative for 70% of topical eye medications**
 - Targeted to prevent contamination of multidose containers
 - **Chronic effect:**
 - Cause of dry eye by impairing tear function (TBUT)
 - Goblet cells
 - Conjunctiva
 - **Effect of BAK Preservative in Eye Drops**
 - **Glaucoma patients at greater risk:**
 - Chronic use of drops
 - Concentration of BAK in IOP-lowering medications:
 - Xalatan - 0.02%
 - Travatan – 0.015%
 - Lumigan – 0.005%
 - 40-50% of patients on more than one medication
 - **BAK Alternatives for IOP-Lowering**
 - **Glaucoma eyedrops with BAK**
 - All with the exception of Alphagan P which uses SOC (stabilized oxychloro complex) and Timoptic XE (with BDD)
 - **Non preserved chronic use drops must be single use (ex. Timoptic)**
 - Very expensive
 - Inconvenient packaging
 - Special ordering
 - **BAK Alternatives for IOP-Lowering**
 - **Need for a BAK alternative in glaucoma patients**
 - Elderly patients with decreased tear secretion
 - On meds for life
 - Multiple topical medications
 - May undergo filtering surgery
 - **SofZia – Alternative Preservative**
 - **SofZia composed of ions and buffers of hydrogen borate, sorbitol and zinc.**
 - **Less toxic to human corneal epithelial cells as measured in culture**
 - As compared to Xalatan and gentamicin

- Since 1953, FDA requires multidose ophthalmic preparations contain a preservative to reduce contamination
- BAK is in most ophthalmic medications (72%)
- Decrease risk of microbial contamination in the bottle
- Benzalkonium Chloride (BAK)
 - Cationic surfactant properties (a detergent)
 - Preserves multi-dose containers from microbial contamination
 - Enhances corneal penetration of some drugs by causing epithelium separation
- Preservatives in IOP-Lowering Medications
- Glaucoma Drugs Without BAK
- Drugs
 - Travatan Z with SofZia
 - Brimonidine with Purite
 - Timoptic XE (timolol) (BDD)
 - Ocudose Timoptic (timolol) (preservative-free)
- Efficacy and side effects: Unchanged
- Drawbacks: None
 - Glaucoma Medications With Non-BAK Preservatives
- Summary
- Preservative Free Drops
- Removing BAK does not affect the efficacy of TravatanZ
- Sustained release products in the future could alleviate many of these challenges

Ocular Surface Disease due to Glaucoma Medications

Jacob Brubaker, MD
Sacramento, CA





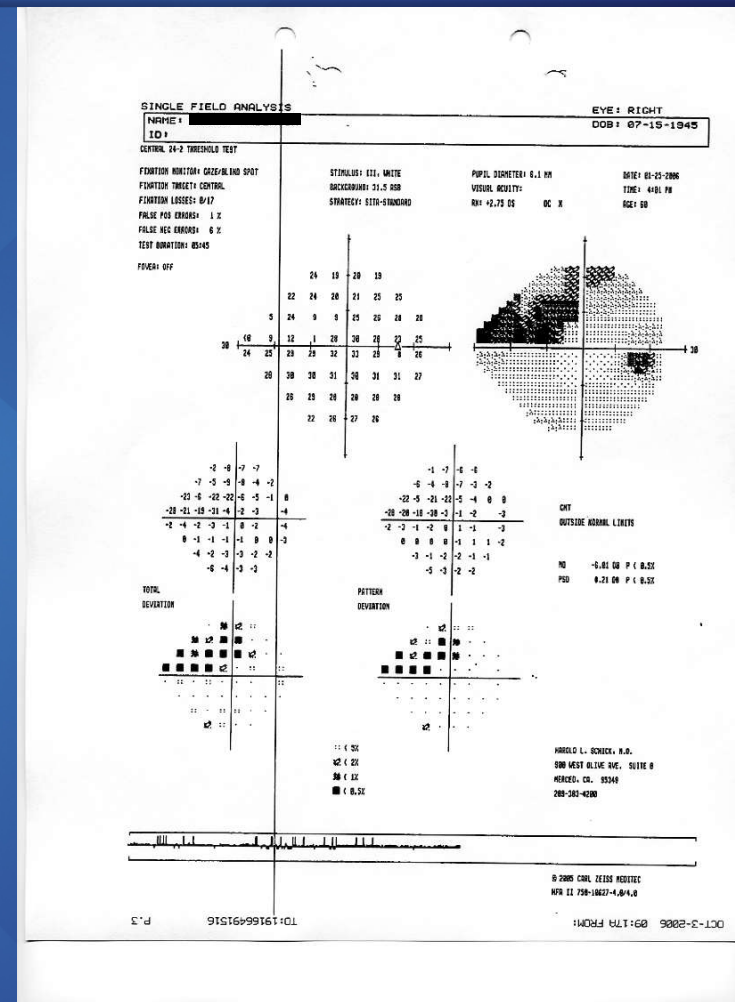
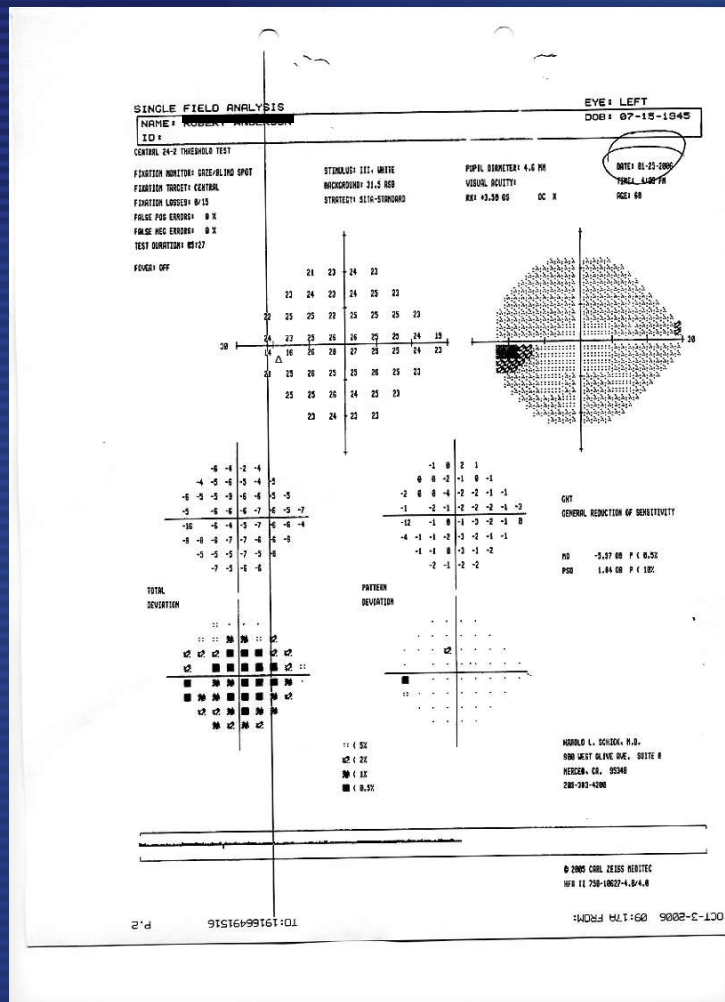
Case Report - RA

- 61 y/o male, complains of red eye OD and lid pigmentation OD
- History of glaucoma for 20 years, first diagnosed with IOP over 50, prior laser Rx OU and cataract surgery OD
- PMH: Healthy
- Meds: Lumigan OD, Timolol OU, Azopt OD, Alphagan OD

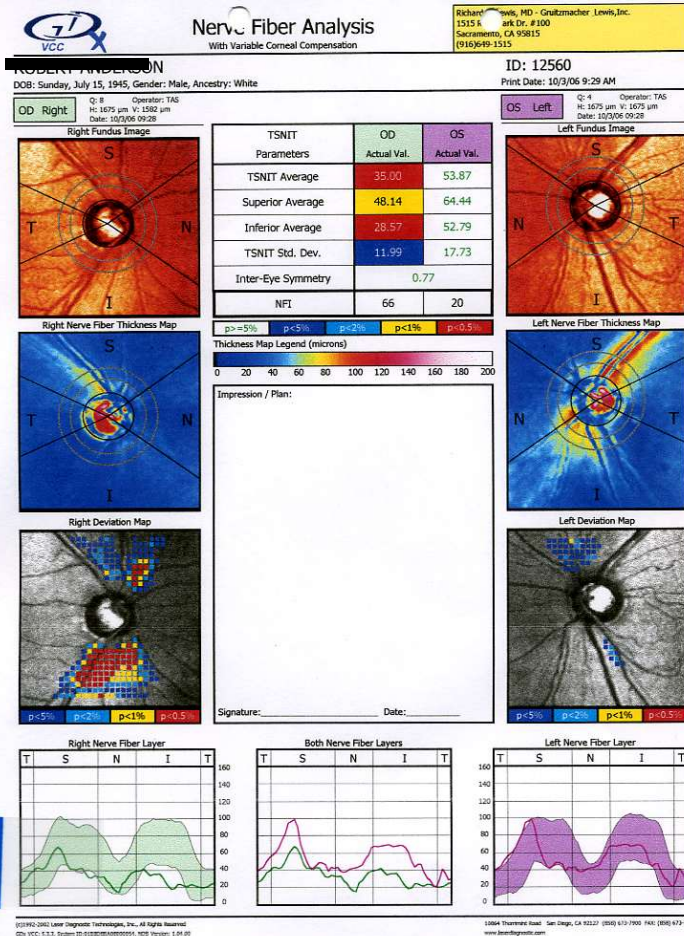
Case Report - RA

● Exam	<u>OD</u>	<u>OS</u>
● Acuity (-1.25)	20/25	20/30
● Pupils	No afferent defect	
● SLE	Long lashes, injection, IOL	
● IOP	30	23
● Gonio	Grade 4 angle OU	
● Fundus	0.8	0.6
● Pachymetry	564	583

Case Report - RA



Case Report - RA



BAK (benzalkonium chloride)

- Preservative used in over 72% of eye drops
- Cationic surfactant properties (a detergent)
- Preserves multi-dose containers from microbial contamination
- Enhances corneal penetration of some drugs by causing epithelium separation

» Abelson: Review of Ophthal 2002

Effect of Preservatives in Eye Drops

- BAK (benzalkonium chloride) is the preservative for 70% of topical eye medications
 - Targeted to prevent contamination of multidose containers
- Chronic effect:
 - Cause of dry eye by impairing tear function (TBUT)
 - Goblet cells
 - Conjunctiva

Effect of BAK Preservative in Eye Drops

- Glaucoma patients at greater risk:
 - Chronic use of drops
 - Concentration of BAK in IOP-lowering medications:
 - Xalatan - 0.02%
 - Travatan – 0.015%
 - Lumigan – 0.005%
 - 40-50% of patients on more than one medication

BAK Alternatives for IOP-Lowering

- Glaucoma eyedrops with BAK
 - All with the exception of Alphagan P which uses SOC (stabilized oxychloro complex) and Timoptic XE (with BDD)
- Non preserved chronic use drops must be single use (ex. Timoptic)
 - Very expensive
 - Inconvenient packaging
 - Special ordering

BAK Alternatives for IOP-Lowering

- Need for a BAK alternative in glaucoma patients
 - Elderly patients with decreased tear secretion
 - On meds for life
 - Multiple topical medications
 - May undergo filtering surgery

SofZia – Alternative Preservative

- SofZia composed of ions and buffers of hydrogen borate, sorbitol and zinc.
- Exceeds USP requirements for bacteria, fungi
- Less toxic to human corneal epithelial cells as measured in culture
 - As compared to Xalatan and gentamicin

IOP-Lowering TRAVATAN® Z Solution and TRAVATAN® Solution

Study Design:

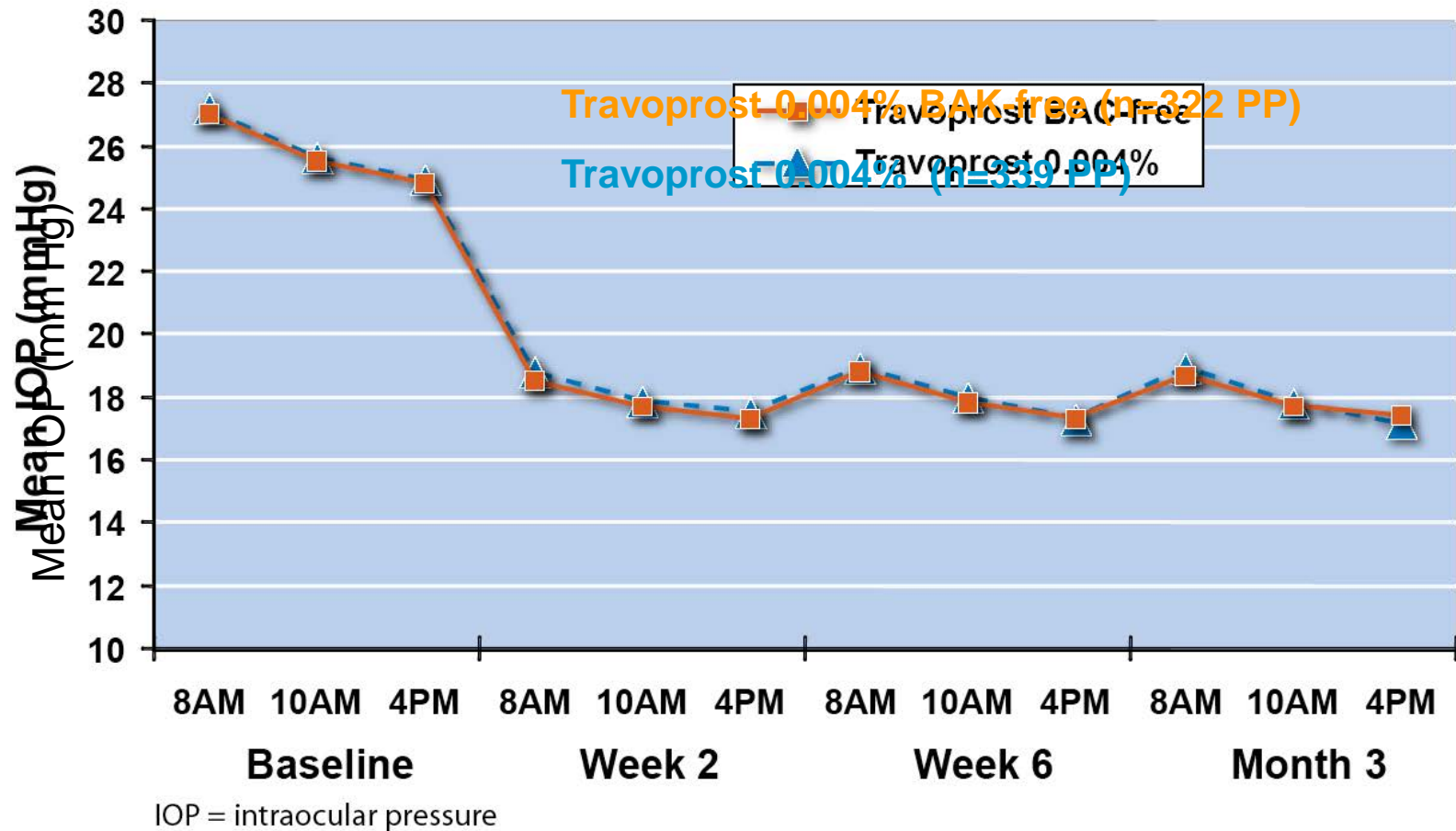
- Double masked, randomized, parallel group, multi-center
- 3 month study
- Dosed once daily in PM
- IOP measured: 8 AM, 10 AM, 4 PM at weeks: 2, 6, 12
- N= 346 randomized to travoprost 0.004%
- N= 344 randomized to travoprost 0.004% BAK-free

Equivalent IOP-Lowering TRAVATAN® Z Solution and TRAVATAN® Solution

Study Results

- Across all 9 study visits, mean IOP reduction range:
7.3 – 8.5 mm Hg travoprost 0.004% BAK-free
7.4 – 8.4 mm Hg travoprost 0.004%
- Statistical equivalence was also demonstrated for the comparison of mean IOP changes
- 6.4% of patients treated with travoprost BAK-free experienced an adverse event due to hyperemia

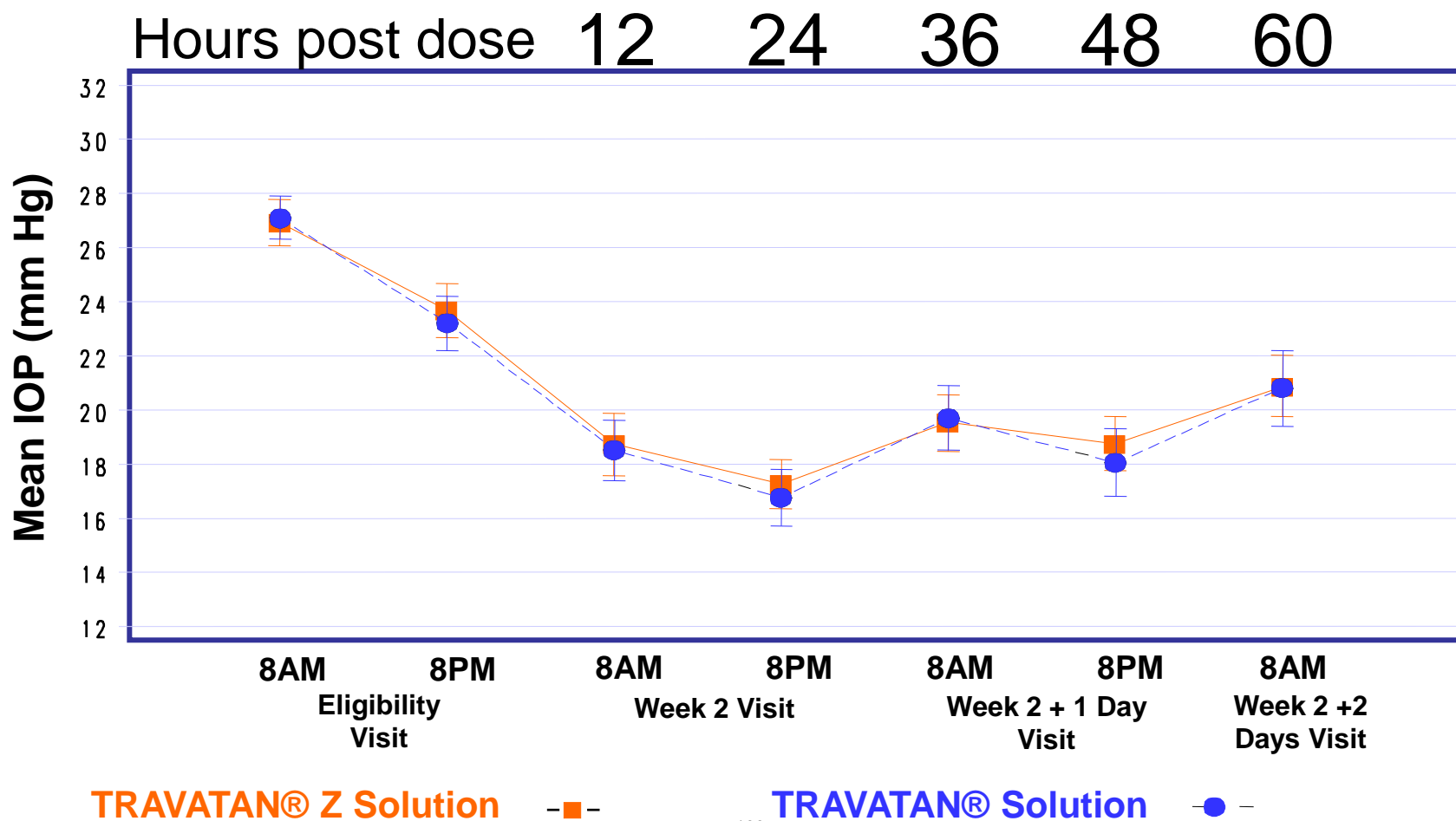
Equivalent IOP-Lowering TRAVATAN® Z Solution and TRAVATAN® Solution



Endurance of IOP-Lowering Study Design

- Double masked, randomized, parallel group, multi-center
- 2 week study
- Dosed once daily in PM
- IOP measured: 8 AM and 8 PM at baseline and beginning at week 2 for 60 hours after the last dose
- N= 52 randomized to travoprost 0.004%
- N= 54 randomized to travoprost 0.004% BAK-free

Equivalent Endurance of IOP-Lowering TRAVATAN® Z Solution and TRAVATAN® Solution



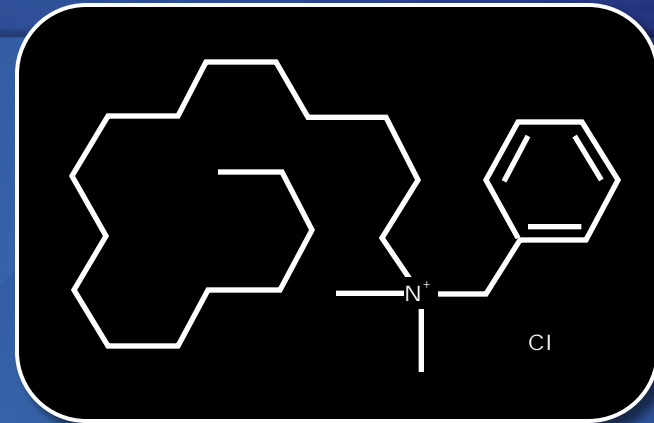

IOP-Lowering Conclusions

- IOP-lowering of TRAVATAN® Z Solution is equal to original TRAVATAN® Solution
- The IOP-lowering endurance of TRAVATAN® Z Solution, beyond 24 hours, is equal to original TRAVATAN® Solution

Ophthalmic Preservatives

- Since 1953, FDA requires multidose ophthalmic preparations contain a preservative to reduce contamination
- BAK is in most ophthalmic medications (72%)
- Decrease risk of microbial contamination in the bottle

Benzalkonium Chloride (BAK)



- Cationic surfactant properties (a detergent)
- Preserves multi-dose containers from microbial contamination
- Enhances corneal penetration of some drugs by causing epithelium separation

Preservatives in IOP-Lowering Medications

Trade Name	Manufacturer	Preservative
Alphagan ¹	Allergan, Inc	0.005% BAK
Alphagan P ¹	Allergan, Inc	0.005% SOC
Azopt Suspension ¹	Alcon Laboratories, Inc	0.01% BAK
Betagan ¹	Allergan, Inc	0.005% BAK
Betoptic S Suspension ¹	Alcon Laboratories, Inc	0.01% BAK
Cosopt ¹	Merck & Co, Inc	0.0075% BAK
Lumigan ²	Allergan, Inc	0.005% BAK
Rescula ¹	Novartis Ophthalmics	0.015% BAK
Timoptic ¹	Merck & Co, Inc	0.01% BAK
Timoptic-XE ¹	Merck & Co, Inc	0.012% BDD
Travatan Solution ³	Alcon Laboratories, Inc	0.015% BAK
Trusopt ¹	Merck & Co, Inc	0.0075% BAK
Xalatan ¹	Pfizer Inc	0.02% BAK

1. Noecker R. *Rev Ophthalmol*. 2001(6).

2. Lumigan package insert.

3. Travatan package insert.

Travoprost 0.004% With and Without BAK

- Purpose

- To compare the safety and efficacy of travoprost with and without BAK

- Inclusion criteria

- IOP between 24 and 36 after washout
- At least 1 eye had to qualify for each of the 6 time points

Travoprost BAC-Free Study Group

- Jason Bacharach
- Stan Berke
- Randy Craven
- William Davitt, III
- Douglas Day
- Efraim Duzman
- Richard Evans
- Catherine Fitzmorris
- Ron Frenkel
- Mark Gorovoy
- Tom Henderson
- Bret Hughes
- Jane Hughes
- Martin Kaback
- Greg Katz
- Michael Kottler
- Bradley Kwapiszeski
- Richard Lewis
- Jeffery Lozier
- Eugene McLaurin
- Katherine Ochsner
- James Pearce
- Ravi Reddy
- Tushina Reddy
- Ned Reinstein
- Michael Rotberg
- Ken Sall
- Paul Scharcknow
- Howard Schenker
- Stephen Scoper
- Elizabeth Sharpe
- Robert Shields
- Shannon Smith
- Emil Stein
- Robert Sterwart
- Michael Tepedino
- Stuart Terry
- Robert Thomas
- George Thorne
- Jonathan Stanwood Till
- Nikhil Wagle
- Thomas Walters
- Mark Weiss
- Robert Williams

Travoprost 0.004% With and Without BAK

- Study design

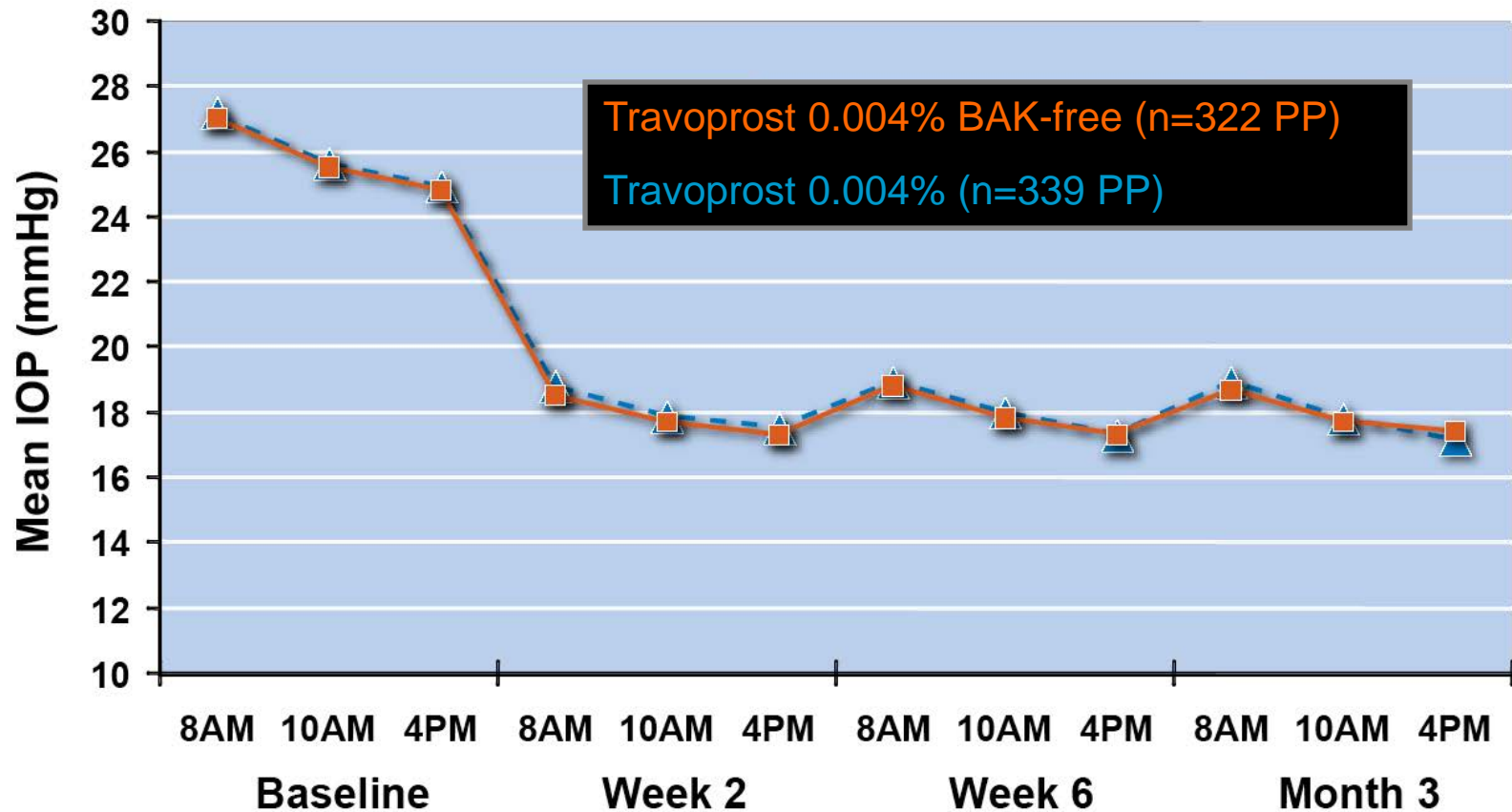
- Double-masked, randomized, parallel-group, multi-center study
- 3-month study
- Dosed once daily in PM
- IOP measured 8 AM, 10 AM, and 4 PM at Weeks 2, 6, and 12
- n=346 randomized to travoprost 0.004%
- n=344 randomized to travoprost 0.004% BAK-free

Travoprost 0.004% With and Without BAK

- Study results

- Across all 9 study visits, mean IOP reduction range
 - 7.3–8.5 mm Hg travoprost 0.004% BAK-free
 - 7.4–8.4 mm Hg travoprost 0.004%
- Statistical equivalence also was demonstrated for the comparison of mean IOP changes
- 6.4% of patients treated with travoprost BAK-free and 9.0% treated with original travoprost experienced an adverse event due to hyperemia

Travoprost 0.004% With and Without BAK



Safety and Drawbacks

- Efficacy
 - No change with efficacy with or without BAK
- Side effects
 - No change in hyperemia or iris pigmentation with or without BAK
- Are BAK-free medications advantageous for glaucoma patients with dry eye?
 - Probably but it remains to be determined

Glaucoma Drugs Without BAK

- Drugs
 - Travatan Z with SofZia
 - Brimonidine with Purite
 - Timoptic XE (timolol) (BDD)
 - Ocudose Timoptic (timolol) (preservative-free)
- Efficacy and side effects: Unchanged
- Drawbacks: None

Glaucoma Medications With Non-BAK Preservatives

No Preservative	Purite (stabilized oxychloro complex)	Benzododecinium Bromide	SofZia (buffers of hydrogen borate, sorbitol and zinc)
Ocudose <u>Timoptic</u> (timolol maleate)	<u>Alphagan P</u> (brimonidine) 0.1%, 0.15%	0.012% in <u>Timoptic-XE</u> (timolol maleate)	<u>Travatan Z</u> (travoprost)
Ocudose Pilocarpine 2%, 4% generic (steri-unit)			

Summary

- Preservative Free Drops
- Removing BAK does not affect the efficacy of TravatanZ
- Sustained release products in the future could alleviate many of these challenges

Jacob Wellington Brubaker

1310 Jake Lane • Columbia, Missouri, USA • 65203
Phone: 573-864-7001 • E-mail: jacobbrubaker@gmail.com

EDUCATION

Glaucoma Fellowship:	2012 - 2013 Dean McGee Eye Institute, University of Oklahoma, Oklahoma City, Oklahoma
Ophthalmology Residency:	2009 - present University of Missouri, Columbia, Missouri
Internal Medicine Internship:	2008 - 2009 University of Utah, Salt Lake City, Utah
Pre-Residency Fellowship:	2007 - 2008 University of Utah, Salt Lake City, Utah (ophthalmic pathology)
Medical:	2003 - 2007 M.D. McGill University, Montreal, Quebec
Undergraduate:	1997 - 2003 B.A. History Brigham Young University, Provo, Utah

SPECIAL AWARDS AND HONORS

June 2012	University of Missouri Resident and Alumni Day Award for Silver Medal Research Project <ul style="list-style-type: none">• Vorinostat glaucoma trabeculectomy treatment trial
June 2011	University of Missouri Resident and Alumni Day Award for Silver Medal Research Project <ul style="list-style-type: none">• Sclera-Cornea Intraocular Pressure Extrapolation Study
May 2010	Resident Award for Annual Highest Ophthalmic Knowledge Assessment Program Score University of Missouri
April 2008	ASCRS Best Paper of Session <ul style="list-style-type: none">• Stability of A Novel Photochromic IOL after a Simulated 20 Years in the Eye using a Nd:YAG Laser Exposure Test
May 2007	ARVO poster Travel Award <ul style="list-style-type: none">• Correlation between visual acuity and optical coherence tomography features in patients with age-related macular degeneration using a novel protocol

July 2004	Anatomy Prosection Research Award, McGill University, Dr Ayman Behiery
2002 – 2003	Roy Richins Scholarship, Brigham Young University
2001 – 2003	Deans List, Brigham Young University
1997 - 1998	John Dunn Scholarship, Brigham Young University

RESEARCH

May 2011 -present	Research Assistant, University of Missouri, Department of Ophthalmology, Rajiv R. Mohan, PhD <ul style="list-style-type: none"> The use of novel inhibitors of fibrosis in glaucoma filtration surgery
Oct-Nov 2006	Research Assistant, University of Southern California, Department of Ophthalmology, Srinivas Sadda, MD <ul style="list-style-type: none"> Advanced retinal imaging technologies: the utility of optical coherence tomography in predicting visual acuity in age related macular degeneration
2001 – 2003	Research Assistant, Brigham Young University, Department of Physiology and Developmental Biology, R. Ward Rhee, PhD <ul style="list-style-type: none"> Steroid hormone-brain interactions: the effect of phytoestrogen on neurological and behavioral development

PUBLICATIONS

Brubaker JW, Harrie RP, Patel BC, Davis DK, Mamalis N. CT and Orbital Ultrasound Findings in a Case of Castleman Disease. *Ophthalmol Plast Reconstr Surg.* 2011; 27: 37-9

Cutler Peck CM, Brubaker J, Clouser S, Danford C, Edelhauser HE, Mamalis N. Toxic anterior segment syndrome: common causes. *J Cataract Refract Surg.* 2010; 36:1073-80.

Mamalis N, Grossniklaus HE, Waring GO 3rd, Werner L, Brubaker J, Davis D, Espandar L, Walker R, Thyzel R. Ablation of lens epithelial cells with a laser photolysis system: histopathology, ultrastructure, and immunochemistry. *J Cataract Refract Surg.* 2010; 36:1003-10.

Agarwal A, Brubaker JW, Mamalis N, Dhivya A, Soosan J, Sujatha C, Agarwal A, Alessandro M. Femtosecond assisted lamellar keratoplasty (FALK) in Avellino corneal dystrophy. *Eye Contact Lens.* 2009; 35:272-4

Brubaker JW, Bale Jr JF, Ampofo K, Dries DC. Congenital cytomegalovirus infection: progressive post-natal chorioretinitis. *J Pediatr Ophthalmol Strabismus.* 2009; 49:249-51

Keane PA, Bhatti RA, Brubaker JW, Liakopoulos S, Sadda SR, Walsh AC. Comparison of clinically relevant findings from high-speed fourier-domain and conventional time-domain optical coherence tomography. *Am J Ophthalmol.* 2009; 148:242-248

Davis D, **Brubaker J**, Espandar L, Stringham J, Crandall A, Werner L, Mamalis N. Late in-the-bag spontaneous intraocular lens dislocation: evaluation of 86 consecutive cases. *Ophthalmology*. 2009; 116:664-70

Brubaker JW, Mohny BG, Pulido JS. Cystoid macular edema in a patient with chronic progressive external ophthalmoplegia with mitochondrial myopathy. *Ophthalmic Genet*. 2009; 30:50-3

Werner L, Tassignon MJ, Gobin L, Rozema J, Davis D, **Brubaker J**. Bag-in-the-lens: first pathological analysis of a human eye obtained postmortem. *J Cataract Refract Surg*. 2008; 34:2163-5.

Brubaker JW, Mohny BG, Pulido JS. Vitreous veils and radial lattice in Marshall syndrome. *Ophthalmic Genet*. 2008; 29:184-5

Mamalis N, **Brubaker JW**, Davis D, Espandar L, Werner L. Complications of foldable intraocular lenses requiring explantation or secondary intervention-2007 survey update. *J Cataract Refract Surg*. 2008; 34:1584-91.

Price MO, Baig KM, **Brubaker JW**, Price FW Jr. Randomized, prospective comparison of pre-cut vs. surgeon-dissected grafts for Descemet's stripping automated endothelial keratoplasty. *Am J Ophthalmol*. 2008; 146:36-41

Joeres S, Kaplowitz K, **Brubaker JW**, Updike PG, Collins AT, Walsh AC, Romano PW, Sadda SR. Quantitative comparison of optical coherence tomography after pegaptanib or bevacizumab in neovascular age-related macular degeneration. *Ophthalmology* 2008; 115:347-354

Mamalis N, **Brubaker JW**: Chapter: Anophthalmos. *eMedicine: Ophthalmology*. (<http://emedicine.medscape.com/article/1201354-overview>), 2010

PRESENTATIONS

Brubaker JW, Vorinostat glaucoma trabeculectomy treatment trial, Resident and Alumni Day Presentation University of Missouri, June 8, 2011 (Paper) *Silver Medal Prize*

Brubaker JW, Schoenleber D, Soni C, Fox JA, Reyes M, Sclera-Cornea Intraocular Pressure Extrapolation Study, ASCRS, April 21, 2012 (Paper)

Brubaker JW, Sclera-Cornea Intraocular Pressure Extrapolation Study, Resident and Alumni Day Presentation University of Missouri, June 3, 2011 (Paper) *Silver Medal Prize*

Brubaker JW, Histopathologic Analysis of DLEK, DSEK, DSAEK Failures, Resident and Alumni Day presentation University of Missouri, May 22, 2010 (Paper)

Mamalis N, **Brubaker JW**, Davis DK, Espandar L. ASCRS/ESCRS Survey on Foldable IOLS Requiring Explantation or Secondary Intervention: 2007 Update. AAO November 9, 2008. (Poster)

Brubaker JW, Espandar L, Davis DK, Wilcox C, Mamalis N. Stability of a novel photochromic IOL after simulated 20 years in the eye using Nd:YAG laser exposure test. ASCRS April 7, 2008. (Paper) ASCRS *Best Paper Of Session*

Espandar L, **Brubaker JW**, Davis DK, Mamalis N, Werner L. Evaluation of accommodating IOL in cadaver eye using a modified Miyake technique. ASCRS April 5, 2008. (Paper)

Mamalis N, **Brubaker JW**, Davis DK, Espandar L. ASCRS/ESCRS survey of foldable IOL's requiring explantation of secondary intervention—2007 update. ASCRS April 8, 2008. (Paper)

Mamalis N, Grossniklaus HE, Waring GO, **Brubaker JW**, Davis DK, Espandar L. Histopathologic analysis of ablation of lens epithelial cells with a laser photolysis system. ASCRS April 8, 2008. (Paper) ASCRS *Best Paper Of Session*

Romano P, Joeres S, Kaplowitz K, **Brubaker JW**, Updike P, Walsh AC, Sadda SR. Quantitative comparison of short-term anatomic response following pegaptanib versus bevacizumab treatment for neovascular age-related macular degeneration. Invest Ophthalmol Vis Sci. 270-B323. ARVO May 6, 2007. (Poster)

Brubaker JW, Joeres S, Kim LA, Sadda SR, Walsh AC. Differences in external limiting membrane visualization between Fourier domain and time domain optical coherence tomography. Invest Ophthalmol Vis Sci. 2618-B695. ARVO May 7, 2007. (Poster)

Wang M, Joeres S, **Brubaker JW**, Walsh AC, Sadda SR. Correlation between visual acuity and optical coherence tomography features in patients with age-related macular degeneration using a novel protocol. Invest Ophthalmol Vis Sci. 5120-B268, ARVO May 10, 2007. (Poster) ARVO *travel award winner*

Joeres S, Kaplowitz K, **Brubaker JW**, Updike PG, Collins AT, Walsh AC, Romano PW, Sadda SR. Quantitative comparison of optical coherence tomography data following intravitreal bevacizumab, ranibizumab or pegaptanib treatment for neovascular age-related macular degeneration. DOG, Berlin, Germany 2007 (Poster)

VOLUNTEER ACTIVITIES

Feb 2010	Ophthalmology medical mission and disaster relief, Port-au-Prince, Haiti
Dec 2004	Clinical humanitarian service, Koussanar, Senegal, Africa
1998 - 2000	Official Representative, The Church of Jesus Christ of Latter-day Saints, Quebec, Canada

WORK EXPERIENCE

2007-2008 Recovery Technician, Utah Lions Eye Bank

Summer 2004 Website Developer, "Clinical Hematology" Student Study Tool
Molson Medical Informatics, McGill University

2001 - 2003 Chemistry Teaching Assistant, Brigham Young University

Fall 2001 Physiology Lab Assistant, Brigham Young University

Summer 2001 Planning Assistant, Foundations of Leadership Conference, Brigham
Young University

QUALIFICATIONS AND CERTIFICATIONS

USMLE step I	August 22, 2005	Score: 233/94
USMLE Step II CS	April 25, 2007	Score: 255/99
USMLE Step II CK	May 1, 2007	Score: Pass
USMLE Step III	Feb. 26, 2009	Score: 233/99

HOBBIES AND INTERESTS

Mountain biking, water skiing, downhill and cross-country skiing, backpacking, hiking, camping, cooking, gardening and landscaping, photography, movie editing, speaking and improving my french, travel, attending art museums, spending time with my family.

LANGUAGES

English: mother tongue

French: spoken